

# Differential Diagnosis and Management of Spinal Nerve Root-related Pain

---

Phillip S. Sizer Jr., MEd, PT, PhD(c)<sup>\*,†</sup>; Valerie Phelps, PT<sup>†</sup>; Greg Dedrick, MPT<sup>†</sup>; Omer Matthijs, PT<sup>‡</sup>

*\*Texas Tech University Health Sciences Center, †International Academy of Orthopedic Medicine-US, ‡International Academy of Orthopedic Medicine-Europe*

■ **Abstract:** Pain originating from spinal nerve roots demonstrates multiple pathogeneses. Distinctions in the patho-anatomy, biomechanics, and pathophysiology of spinal nerve roots contribute to pathology, diagnosis, and management of root-related pain. Root-related pain can emerge from the tension events in the dura mater and nerve tissue associated with primary disc related disorders. Conversely, secondary disc-related degeneration can produce compression on the nerve roots. This compression can result in chemical and mechanical consequences imposed on the nervous tissue within the spinal canal, lateral recess, intervertebral foramina, and extraforminal regions. Differences in root-related pathology can be observed between lumbar, thoracic, and cervical spinal levels, meriting the implementation of different diagnostic tools and management strategies. ■

**Key Words:** root, dura, tension, compression, fibrosis, flossing

## INTRODUCTION

Pain originating from spinal nerve roots demonstrates multiple pathogeneses. Root-related pain can emerge from the tension events in the dura mater and nerve tissue associated with primary disc related disorders, including disc protrusion, prolapse, and extrusion. Conversely, secondary disc-related degeneration can produce compression on the nerve roots within the surrounding “container,”<sup>1</sup>

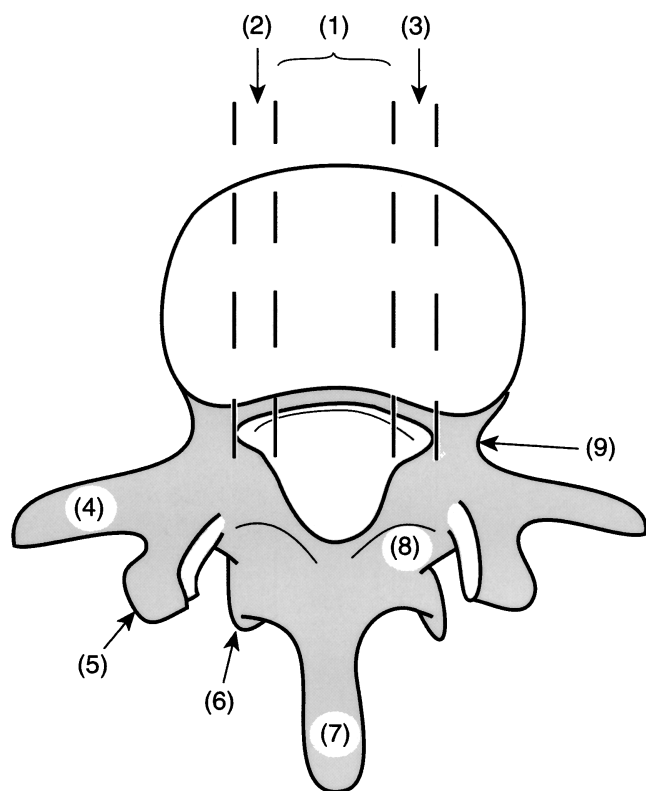
resulting in chemical and mechanical consequences imposed on the nervous tissue within the spinal canal, lateral recess, intervertebral foramina, and extraforminal regions. In order to understand root-related pain, the normal and pathological anatomy, biomechanics and pathophysiology of spinal nerve roots must be reconsidered. Additionally, one must evaluate the differences in those processes that can be observed between lumbar, thoracic, and cervical spinal levels in order to understand the propensity for specific afflictions in those regions.

## Lumbosacral Spinal Canal, Lateral Recess, and Foraminal Zone

Lumbar and sacral vertebral canals are developmentally equivalent in cross sectional area during the first 14 weeks in utero. After 14 weeks, the lumbar canal develops at a faster rate than the sacral canal. In addition, the lumbar canal achieves an adult size within the first 12 months postpartum at the L3 and L4 bony levels. If bony growth is impaired during an infant’s early development, the upper lumbar region may be pre-disposed to compression of neural tissue within the central spinal canal, lateral recess, and foraminal regions. Conversely, the canal at the fifth lumbar segment develops more slowly and does not reach an adult size until the fifth year, thus providing the canal an opportunity to “catch up” if development is delayed in utero or early infancy.<sup>2</sup>

Bony and soft tissue structures comprise the boundaries of the spinal canal and the relative contribution of these structures differs at various levels within each bony segment. A cranial view of the lumbar bony segment reveals several important regions associated with

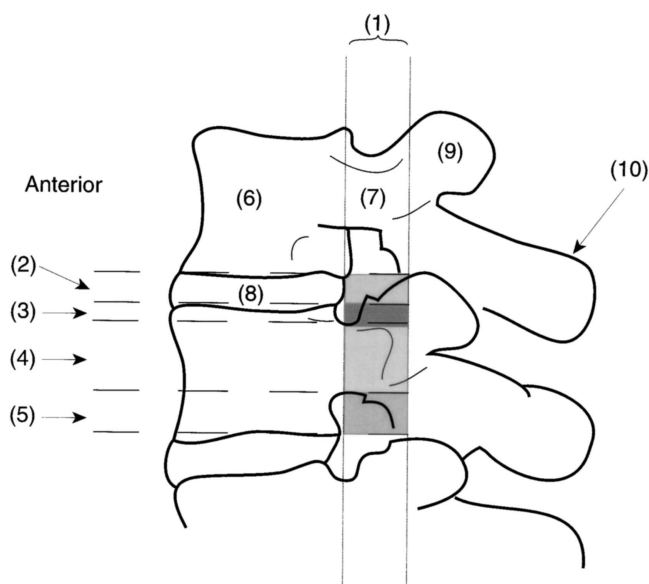
Address all correspondence and reprint requests to: Phillip S. Sizer Jr, MEd, PT, PhD(c), Texas Tech University Health Sciences Center, School of Allied Health, Physical Therapy Program, 3601 4<sup>th</sup> St., Lubbock, TX 79430, U.S.A.



**Figure 1.** Cranial View of the Spinal Canal. (1) Left/Right Limits of the Spinal Canal; (2) Limits of the Left Lateral Recess; (3) Limits of the Right Lateral Recess; (4) Left Transverse Process; (5) Left Superior Articular Process; (6) Left Inferior Articular Process; (7) Spinous Process; (8) Right Pars Interarticularis; (9) Right Pedicle

the course of the nerve root (see Figure 1). One notes the central canal zone in the middle of the spinal canal. The sub-articular zone (or lateral recess) comprises the lateral region of the canal and is found between the articular process (posteriorly) and the vertebral body (anteriorly). Nerve roots course through this recess after exiting the dural sac en route to the foraminal zone of the intervertebral foramen. These roots are positioned further away from the inferior pedicle and closer to the superior pedicle.<sup>3</sup> Finally, lumbar roots exit the confines of the axial skeleton through the extraforminal (or far-lateral) zone.<sup>4</sup> This orientation in the lumbar spine predisposes lumbar roots to chemical and mechanical irritation, secondary to a close proximity with the disc and zygapophyseal articular processes.

From a lateral view, the lumbar spinal canal can be vertically divided within each segment into supra-pedicular, pedicular, infra-pedicular and disc levels (see Figure 2). The vertebral bodies, posterior longitudinal ligament (PLL) and venous plexus of Batson border the canal on the ventral side at all levels of each segment. At the supra-



**Figure 2.** Levels of the Spinal Canal, Lateral View. (1) Anterior and Posterior Limits of the Spinal Canal; (2) Discal Level; (3) Suprapedicular Level; (4) Pedicular Level; (5) Infrapedicular Level; (6) Vertebral Body; (7) Pedicle; (8) Intervertebral Disc; (9) Superior Articular Process; (10) Spinous Process

pedicular canal level, the superior articular processes of the bony segment border the canal posteriorly. At the pedicular level of the canal the pedicles, laminae, ligamentum flavum and retrodural fatpad form the lateral and posterior walls of the canal. The intertransverse membranes, inferior articular processes, ligamentum flavum and retrodural fatpad border the infra-pedicular level of the canal. Finally, the intervertebral disc, PLL, zygapophyseal joint (ZAJ) capsule, and ligamentum flavum border the discal level of the canal. Disc derangements, as well as hypertrophic changes in both bony and soft tissue structures in the canal, can lead to neural compromise.<sup>5</sup>

Vertebral bodies can develop degenerative changes that lead to canal compromise. These degenerative changes frequently occur in response to the increased 'wobble' associated with a segmental hypermobility.<sup>6</sup> In response to this hypermobility, the segment attempts to stabilize in context with progressive disc fibrosis and reduced disc height. This adaptation produces ventral, dorsal and lateral lipping on the vertebral body margins, thus representing a segment's attempt to stabilize the hypermobility.<sup>7</sup> Although these bony changes do not serve as a pain generator, they can reduce the diameter of the spinal canal, compress the dural sac and cauda equina, increase intradural pressure, and produce root-related pain.

The posterior longitudinal ligament (PLL) is comprised of two layers and courses posterior to the verte-

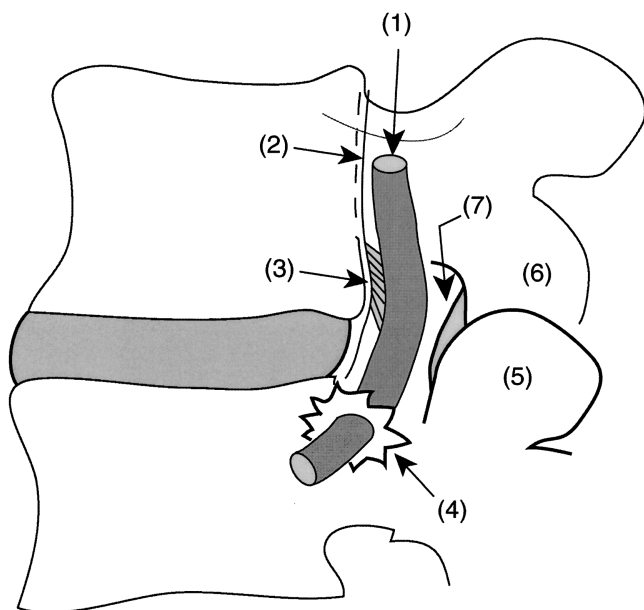
bral column on the anterior wall of the spinal canal. The superficial layer is 8-10 mm wide and extends along the midline of the column from the cervical to sacral bony levels. Deeper fibers of the superficial PLL are hourglass shaped and fan out laterally, attaching to the posterior disc-annulus complex. The deep layer of the PLL is very narrow (2 to 3mm width) and is continuous with the hourglass shape of the superficial PLL, attaching to the lateral borders of the annulus and loosely to the vertebral body. Superficial and deep layers of the PLL are interconnected at each level where the deep layer joins the disc-annulus complex.<sup>8-11</sup> The ligaments of Hoffmann (LOH) connect the dura with the superficial layer of the PLL (see Figure 3). The fibers of the LOH, which are confluent with the PLL-annular complex, course dorsal to attach to the dura. They are wider cranially and demonstrate considerable anatomic variation in their attachments and configurations.<sup>12</sup>

The ligaments of Hoffmann hold the lumbar dura ventrally against the vertebra and secure the dura of the root in a caudal direction as the axial skeleton grows and develops.<sup>10</sup> In addition, the LOH appear to transmit tension forces from the epineurium and dura to the spinal column.<sup>13</sup> Furthermore, the dura mater of the root is attached to the disc and PLL via tight adhesions through these same ligamentous networks. Investigators observed

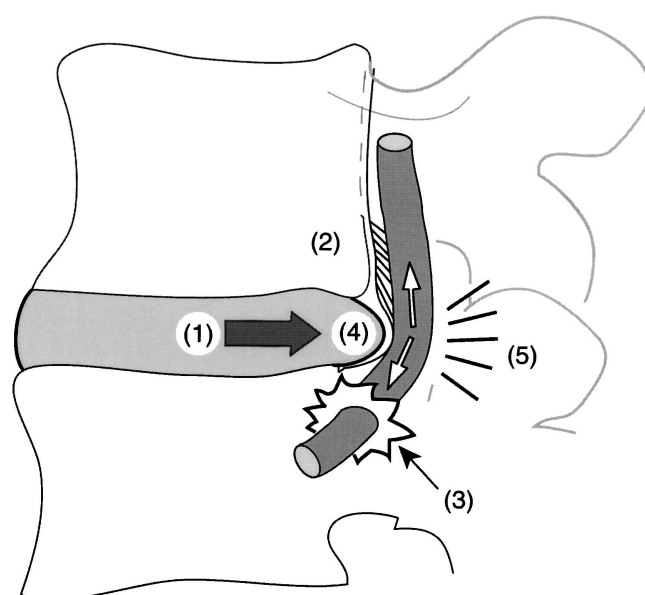
bundles of free nerve endings within the PLL that contained substance P (SP), calcitonin gene-related peptide (CGRP) and nitric oxide (NO), all which support the nociceptive role the PLL plays in the inflammatory and sympathetic sensitization processes of low back pain.<sup>9,14</sup>

Interforaminal ligaments (or Lateral Hoffmann ligaments; LHL) attach the lumbar dural root sleeve complex to the intervertebral foramen (see Figure 3). The LHL serve to decrease posterior displacement of the dural root sleeve with a disc herniation. This can have consequences since LOH and LHL can tension load the dura or the PLL. Thus, any subsequent tension load that is imposed on the root could produce nonradicular, referred pain, either by virtue of chemically activated root sleeve mechano-sensitivity or irritation of a mechano-sensitive PLL (see Figure 4).<sup>15,16</sup>

Another important structural consideration involves the anterior and posterior internal vertebral venous plexi (or plexi of 'Batson'). These plexi are comprised of an ongoing maze of valveless veins coursing cranially and caudally within and along the ventral and dorsal surfaces of the epidural membrane.<sup>5,17,18</sup> Branches from these veins perforate the peridural membrane at several intervals to enter the vertebral body. However, most veins course uninterrupted across the PLL/annulus complex at the level of the disc. Blood from the vertebral bodies enters the venous system at the nutrient foramina



**Figure 3.** Connections and Container of the Left L4 Root. (1) Root; (2) Posterior Longitudinal Ligament; (3) Ligaments of Hoffman; (4) Interforminal Ligaments; (5) Left Superior Articular Process, L5; (6) Left Inferior Articular Process, L4; Ligamentum Flavum, ZAJ capsule of Left ZAJ



**Figure 4.** Relationship of a 1° Disc Affliction on the Left L4 Root. (1) Intervertebral Disc, L4L5; (2) Ligaments of Hoffman under Tension Load; (3) Interforminal Ligaments under Tension Load; (4) Disc Protrusion; (5) L4 Root under Tension Load with Resulting Ventral/Transverse Compression Stress.

near central points on the posterior surface of the vertebral body. Additionally, blood can course in the opposite direction with changes in abdominal pressure.<sup>10,17</sup> Thus, the entire plexus serves as a blood reservoir to stabilize pressure in and around the axial skeleton.

Because the plexi are valveless, they are subject to poor drainage and resultant distension. This distention is most frequently observed at L3L4 and L4L5, coupled with a compromised canal size at those levels associated with degenerative changes. Furthermore, this venous engorgement can trigger an inflammatory cascade, fibrosis and increased epidural pressure<sup>19,20</sup> that can produce intermittent neurogenic claudications (INC) and or nerve root compression syndrome (NRCS), especially when more than one spinal level demonstrates these changes.<sup>21</sup> Finally, this mechanism may explain why therapeutic traction and abdominal stabilization exercises may decrease symptoms, as those activities could reverse the engorgement process by altering pressure gradients.

The intertransverse membrane extends between the transverse processes of the lumbar spine. More importantly, it extends between the lateral aspects of the ZAJ's and pars interarticularis, thus surrounding the dorsal root ganglion (DRG) and nerve root with collagenated membrane, extraforaminal fat and connective tissue. As result, any tension load imposed on the intertransverse membrane may irritate the DRG. This irritation may be accentuated with segmental hypermobility and warrants neural flossing, so to lessen the sequelae of nerve root and DRG entrapment.<sup>22</sup>

The ligamentum flavum is confluent with the anterior capsule of the ZAJ and closes the posterior spinal canal between the lamina (see Figure 3). This ligament reveals a rich elastin fiber concentration, producing capsular flexibility coupled with elastic stability to the posterior axial skeletal mechanism. This ligament is continuously pre-tensioned in all positions of the spine, precluding any anterior buckling of the normal ZAJ capsule into the spinal canal. However, this ligament demonstrates a potential for hypertrophy with chronic inflammation and or hypermobility and acts as a key contributor to nerve root compression syndrome.<sup>5</sup>

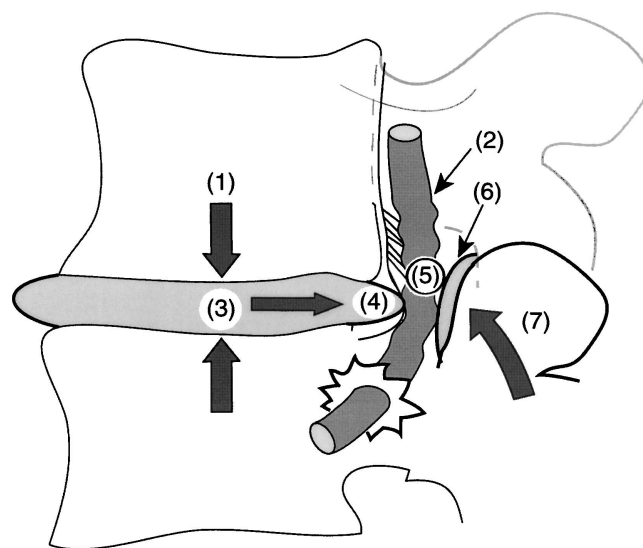
Lumbar segmental hypermobility can eventually lend to hypertrophic changes in the ZAJ articular processes. When these processes hypertrophy in concert with the posterior bulging of a 'flattened' degenerative disc, the cross sectional areas of the spinal canal, lateral recess, and foraminal zones could be compromised.<sup>23</sup> This compromise is increased with lumbar extension or axial loading<sup>24</sup> and could lend to INC and NRCS, due to

bony stenotic changes. However, long before hypertrophic changes are noticed, the superior articular process of the caudal vertebra in a motion segment can gradually migrate into the foraminal exit zone in response to intervertebral disc degeneration. This migration could reduce the anterior-posterior diameter of the lateral root container, leading to a front-back compression of the nerve root (see Figure 5).<sup>23,25</sup>

Continuing dorsally from the dorsal dura, one witnesses a retrodural fat pad. This fat layer is located in a posterior triangular form of the laminal arch. The layers of retrodural fat are connected to the dorsal dura anteriorly, the lamina laterally, and the ligamentum flavum posteriorly. Small arteries and veins enter the fat at the connection site of the ligamentum flavum.<sup>8</sup> This retrodural fat pad can hypertrophy during secondary disc-related disorders. Additionally, the fat pad bulges anteriorly during trunk extension, thus contributing to the dynamical stenotic processes that produce INC and NRCS. Conversely, it appears that epidural administration of anesthetic agents can shrink this fat and reduce its imposition on nerve roots.

### Meninges

The spinal meninges (dura mater, arachnoid, pia mater) form a protective sheath around the spinal cord and are



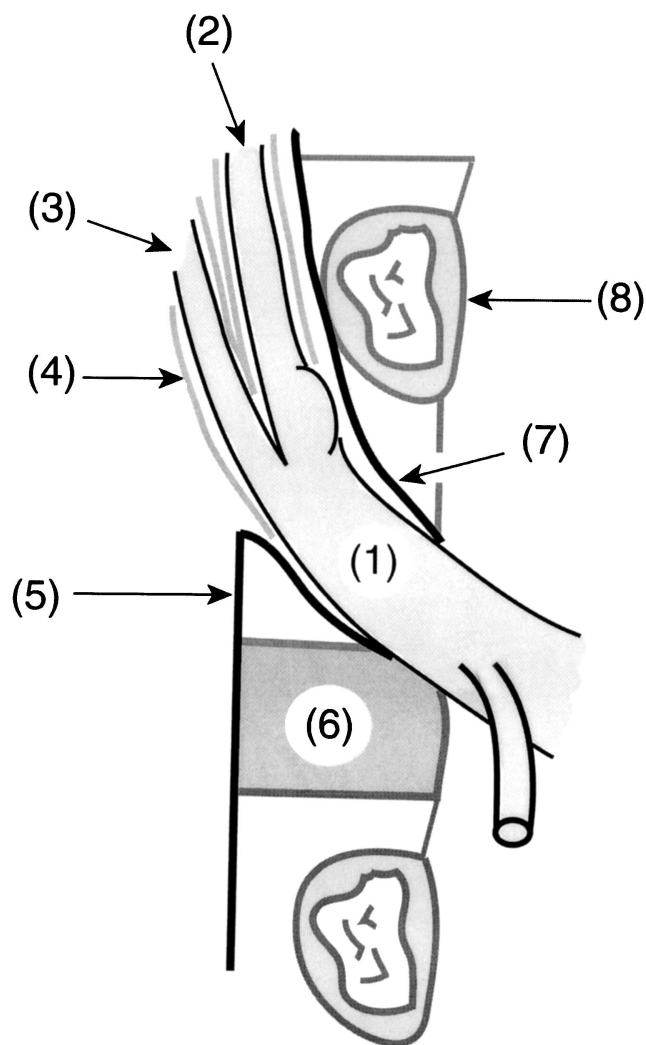
**Figure 5.** Relationship of a 2° Disc Affliction on the Left L4 Root. (1) Degenerative Loss of Intervertebral Space, L4L5; (2) Slackened Nerve Root; (3) Degenerative Intervertebral Disc; (4) Flattened Disc Bulge, with Resulting Ventral Compromise of Root Container; (5) Inflammatory Irritable Focus in Root Zone of Lability; (6) Hypertrophic Ligamentum Flavum and (7) Ventral Cranial Migration of Superior Articular Process of L5, with resulting Dorsal Compromise of Root Container.

anchored to the cord via the dentate ligaments. The subarachnoid space and fibro-adipose tissue protect the spinal cord and meninges from deforming forces.<sup>26</sup> Morphologically, the dura mater is composed of three distinctive layers of collagen.<sup>26,27</sup> These layers are interspersed with elastin fibers, which allow the dura to be displaced with postural changes. The collagen is further organized into 78 to 82 thin interwoven laminae<sup>26,27</sup> that are primarily organized in the longitudinal direction.<sup>28</sup> This organization enhances tensile strength in resistance to longitudinal stress.<sup>29</sup> In addition, fibers are concentrically wrapped around the spinal axis, providing additional transverse tensile strength aimed at protecting the neural tissue.<sup>26,27</sup> Furthermore, 7% to 14% of the dural content is elastin, providing a limited extensibility.<sup>30</sup>

Cranially, the rectus capitis posterior minor muscle (RCPM) has a connective tissue attachment to the suboccipital dura via the posterior atlanto-occipital membrane (PAO). This mechanism serves to resist in-folding of the dura during movements of the upper cervical spine in conjunction with the cranial durae matris spinalis (CDMS). The RCPM contains a large number of mechanoreceptors that suggest it plays a role not only with resisting dural in-folding, but may be involved with proprioceptive disturbances from whiplash-like trauma.<sup>31,32</sup>

The dural sac extends caudally along the entire length of the spinal canal, surrounding the spinal cord down to the conus medullaris and extending further to surround the cauda equina. As the root bundles exit laterally, the pia-arachnoid membranes fuse and surround the fascicles. This results in a deep sulcus of dura forming around the roots as they exit the thecal sac. Once the roots have exited the dural sac, they course within a dural compartment infero-laterally, until fusing together into a spinal nerve.<sup>8,16</sup> This 1 to 2 cm region from the dural sac to just beyond the DRG is typically labeled as the 'nerve root.' However, Wiltse called the dural structure a dural root sleeve, since it contains 2 separate roots (ventral and dorsal) within a dural compartment (see Figure 6).<sup>10</sup>

The dural sleeve extends as far as the lateral margins of the foraminal zone, where the dura becomes confluent with the epineurium<sup>13</sup> and the 2 spinal roots join together to form the spinal nerve.<sup>10</sup> In successive caudal segments, the exiting roots within their dural sleeves exit the dural sac in an increasingly vertical orientation. Along with this changing orientation, the exit point differs at successively caudal root levels. Whereas the L1 root and sleeve emerge dorsal to the L1 vertebral body, the L5 root and sleeve emerge dorsal to the L4L5 inter-



**Figure 6.** Meninges of the Roots. (1) Spinal Nerve; (2) Dorsal Root; (3) Ventral Root; (4) Arachnoid Layer; (5) Dural Sac; (6) Intervertebral Disc; (7) Dural Root Sleeve; (8) Pedicle. Adapted from Bogduk N. *Clinical Anatomy of the Lumbar Spine and Sacrum*. New York: Churchill Livingstone; 1997.

vertebral disc. This variance may give rise to varying impact of primary disc lesions upon nerve tissue at different disc levels.<sup>5</sup>

Dorsally, the spinal dura and dural sleeve does not possess the same nerve supply when compared to the rich somatosensory and visceral efferent nerve supply afforded to the cranial and ventral dura.<sup>14,26,33,34</sup> The dorsal dura is scantily innervated from branches of the ventral dural plexus, whereas the sinuvertebral nerve from several root levels richly innervates the ventral and lateral dura.<sup>5</sup> The sinuvertebral nerve may ascend or descend up to 4 or 5 spinal levels from its point of entry in the dural plexus. This poly segmental innervation may

help explain vague, non-radicular, referred pain associated with a prolonged chemical or mechanical irritation event imposed upon the ventral and lateral dura.<sup>11,33,35,36</sup> Additionally, the cranial, ventral and lateral dura demonstrate greater numbers of SP and CGRP nerve fibers when compared to the dorsal spinal dura. A paucity of SP and CGRP nerve fibers in the dorsal spinal dura suggests the dorsal dura's limited role in pain generation.<sup>14,34</sup> Finally, the sinuvertebral nerve demonstrates a structurally curled appearance, which could allow for length adjustments within the mobile dura during flexion and extension movements.<sup>33</sup> Scar tissue could hinder this mobility, leading to an increased non-radicular referred pain associated with root mobility limitations.

### Selected Anatomical Features of Lumbosacral Nerve Roots

At two years of age, the final resting position of the conus medullaris is set between L1 and L2.<sup>37</sup> In adults without spinal deformity, the conus medullaris can vary in position from the middle third of T12 to the upper third of L3.<sup>38</sup> The conus medullaris represents the end of the caudal tip of the spinal cord whereby continued innervation is carried within the lumbar and sacral plexus making up the cauda equina.

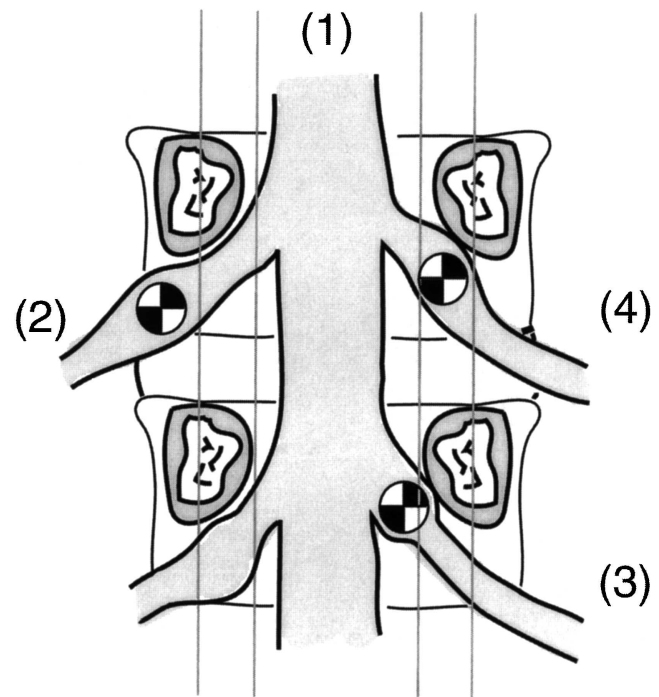
Individual roots within the cauda equina from L2-3 to L5-S1 are organized with the cranial roots being ventral and lateral and caudal roots positioned dorsal and medial.<sup>39-41</sup> Within each nerve root, the motor bundle is positioned anteromedial to its larger sensory counterpart.<sup>42</sup> Nerve roots of the cauda equina are composed of fascicles that are grouped into bundles within the subarachnoid space. Between 1 and 10 fascicles are bound into a bundle by a fine membrane from the pia-arachnoid. Each dorsal root is comprised of 1 to 10 bundles, whereas, the smaller ventral roots are typically formed as a single bundle.

The root receives nutrition from different sources. First, the roots receive nutritive support by diffusion from extrinsic and intrinsic vessels.<sup>43</sup> Extrinsicly, the root receives a blood supply from vascular branches of the large vessels and the arterial tree of the spinal nerve.<sup>16,44</sup> In addition, an intrinsic capillary bed surrounds the root to augment diffusion. However, the vascular supply to the root is less extensive than the supply to the spinal nerve or spinal dura.<sup>45</sup> As a consequence, spinal nerve roots are prone to "neuro-ischemic" response, due to degenerative changes and inflammatory reactions in the lumbar spine.<sup>16,20,40</sup> Secondly, the roots are bathed by cerebrospinal fluid (CSF),<sup>46</sup> as the dural

sleeve is accompanied by a subarachnoid space and pia mater.<sup>16,47</sup> A paucity of CSF is found at the distal insertion of the sleeve, corresponding with the region of poorest capillary perfusion ("a zone of lability"). Thus, this region of the root is especially vulnerable to accelerated irritation and resultant mechanosensitivity.<sup>48</sup>

### The Lumbosacral Dorsal Root Ganglion

The size of the dorsal root ganglion (DRG) varies across the spinal levels. The size progressively increases across the lumbar spine in successive caudal levels down to S1, whereas the size of the DRG decreases caudal to S1. Specifically, the first lumbar DRG is 7 mm in length and 5 mm in width, versus a 13 mm length and 6 mm width at S1. In addition, the position of the DRG varies across spinal levels. Ninety percent of the lumbar DRG's are positioned directly inferior to the pedicle, whereas 8% are positioned inferior and lateral to the pedicle and 2% are located medial to the pedicle within the lateral recess (see Figure 7).<sup>42</sup> Ohmori et al suggested that the location of the DRG within the intervertebral foramen influences the severity of symptoms suffered by patients with an extraforaminal disc lesion, with this risk of irritation increasing when the DRG is more proximally located.<sup>49</sup> Additionally, Sato and Kikuchi found that most S1 DRG's were located in the lateral recess, versus the in-



**Figure 7.** Position of the Dorsal Root Ganglion (DRG). (1) Dural Sac; (2) Extraforaminal Position; (3) Intraspinal; (4) Intraforaminal.

traforaminal location for the L4 and L5 ganglia.<sup>50,51</sup> These features, when coupled with a lateral recess that is longer and narrower, lends the S1 DRG to higher incidence of irritation.

Pain generation from the DRG is both mechanically and chemically mediated. Although the onset of chemically activated root mechanosensitivity and subsequent pain is gradual and progressive, the dorsal root ganglion (DRG) demonstrates immediate increased pressure and pain provocation when it is mechanically deformed.<sup>40,52–55</sup> In addition, neuro-physiological after-discharges can be triggered for up to 25 minutes after the stimulus is removed, even when minor mechanical pressure is exerted upon the DRG. This behavior is the result of high  $\text{Na}^+$  channel concentration in the region of the DRG.<sup>45,56</sup> Thus, the sharp, mechanically-induced projection pain that is produced during the early stages of a primary disc-related disorder is typically related to DRG mechanical deformation,<sup>52</sup> whereas the gradual aching pain that is referred into an extremity is triggered by chemically mediated mechano-sensitivity of the root itself. This information can guide a clinician when planning appropriate management. Whereas mechanical interventions should alter DRG-related pain, pharmacological management may be more effective for chemically triggered radicular pain.<sup>57</sup>

### Lumbar Root Pathomechanics

The connective tissue composition within the root and dural sleeve are sparse in comparison to peripheral nerves.<sup>13,58</sup> Beel et al found in experimental animals that several biomechanical properties were different in a root versus an adjacent peripheral nerve.<sup>13</sup> The investigators found that the root demonstrated significantly lower tissue density, limit force, strength, maximum stiffness and Young's modulus (elasticity modulus; stress/strain). These differences may lend roots to a higher propensity for irritation and injury during tensile and compressive loads.

The movement of the lumbosacral dura is characterized by the orientation and stress responses of the dural collagen fibers. As previously mentioned, the collagen is oriented primarily in the longitudinal direction with respect to the axon orientation. This orientation appears to influence the biomechanical properties of the dura.<sup>28</sup> Runza et al found that stress applied to a dural sample in a longitudinal direction demonstrated a significantly higher ultimate stress and strain, as well as Young's modulus, versus stress applied in a transverse direction.<sup>29</sup> These findings suggest that the dural collagen adapts to

repetitive stretch, producing a stronger tensile strength and greater stiffness in the longitudinal direction.

Movement of the extremities develops tension loads within the nerve roots with variable root motion responses.<sup>13</sup> For example, when the hip is flexed from 0° to 30° during a straight leg raise (SLR), tension is accrued without actual movement of the sacral plexus or cauda equina. Additionally, when the hip is flexed from 30° to 60°, the roots of the sacral plexus move an average of 2 to 5 mm distal-caudal. Furthermore, in the range between 60° and 90° hip flexion, the roots move primarily ventral-lateral toward the ipsilateral pedicles. Finally, there is no caudal movement of the lumbar plexus during straight leg raise.<sup>59</sup> Fibrosis or tethering of the nerve could reduce this motion, leading to irritation and inflammation of the root, resulting in pain. Conversely, this root behavior is not produced to the same extent in the cervical spine during movements of the arm, because cervical roots C5, C6, and often C7 have attachments to the corresponding transverse processes.<sup>60</sup>

Lumbar spine flexion (with the hips in neutral) produces a longitudinal tension loading of the dura,<sup>13,29</sup> cephalad movement of the lower spinal cord<sup>61,62</sup> and consequential movement of the sacral plexus in a direction similar to that observed in the last 30° of SLR. During the same trunk movement, the roots of the lumbar plexus move cranially.<sup>63</sup> This trunk movement-induced root tension may produce clinical consequences. Schnebel et al found that segmental flexion increased the tension load on the ventral root, while extension decreased the same load.<sup>64</sup> In addition, the investigators suggested that the root tension event associated with trunk flexion could increase the transverse compression force of a disc lesion against the root. This increased tension occurs because the nerve root is fixed both at its exit from the thecal sac (via LOH) as well as at its exit through the intervertebral foramen (via interforaminal ligaments). In these young patients, in whom the disc height is preserved (not allowing for any slack in the nerve root), there would be a considerable increase in tension at the edges of the compressive root deformation, or the so-called "edge-effect".<sup>65</sup> Finally, Schnebel et al suggested that longitudinal tension loads imposed on the root through clinical testing could reproduce this same root deformation and subsequent symptoms.<sup>64</sup>

As stated above, an inflamed root is susceptible to *compression* by the disc. It is well documented that tension causes a decrease in arterial and venous blood flow at the root level, as well as a decrease in the nutritional

transport of cerebrospinal fluid.<sup>65,66</sup> This local ischemia is one of the factors (together with the chemical reaction that takes place when disc material contacts the nerve root) that could cause a local chemical reaction at the nerve root, leading to inflammation and edema.<sup>40,67</sup> Thus, when tension increases during movement, compression by the disc against the irritated nerve root also increases, accompanied by increased radicular pain. Smyth and Wright produced root pain when a slight pull was exerted upon nylon threads that were looped around affected roots during disc surgery.<sup>68</sup> However, this investigation did not determine whether the loops around the affected roots were causing the pain (local compression). In addition, it did not identify whether this type of pull was an accurate representation of an *in vivo* response. Thus, the relative contribution of root tensile stress versus root inflammation in symptom provocation is unclear, as they usually occur simultaneously.

This dilemma may be better understood by evaluating the events that occur during different lumbar pathogeneses. In young adults, a protruding disc deforms the associated nerve root, bringing the root under tension.<sup>69</sup> The local ischemia, in concert with disc contact against the ventro-lateral nerve root,<sup>40</sup> triggers a release of chemical substances that activates a true chemical irritation of the root. Consequently, this “focus” of inflammation becomes a pain generator when mechanically stressed by the disc, demonstrating that pain is a consequence of both chemical and mechanical factors.<sup>40,70</sup> In addition, the young disc has not yet lost height, resulting in a limited root mobility that is related to proximal and distal attachments to surrounding structures. Consequently, the root is more rapidly tension loaded, resulting in a significantly greater amount of transverse stress exerted against the irritated site (see Figure 4). Therefore, root-related symptoms associated with a young primary disc-related disorder arise as a consequence of disc turgor, limited root mobility, root tension loading, and root irritability. This event will be later referred to as a diagnostic “Tension Event.”

For the root-related pain associated with secondary disc-related disorders, a narrowed disc space produces a loss in segmental height and subsequent root relaxation (or “slackening”).<sup>69</sup> However, dural testing can produce pain with this disorder even though the root is slackened. In this instance, the irritable focus on the root is pulled through a true compression site that is created by posterior bulging of the flattened disc and anterior migration of the retrodural fatpad, ligamentum flavum, and/or the ZAJ articular process from the caudal bony

segment (FRONT-BACK compression).<sup>40</sup> Thus, pain is elicited because of a mechanical compressive event on the root versus the tension event witnessed with a primary disc-related disorder (see Figure 5). As a consequence, testing this condition will produce outcomes that will differ from those produced during a primary disc-related disorder, as discussed further in “Dural Testing.”

### Thoracic Considerations

The shape of the thoracic spinal canal is small and round in concert with short, thick pedicles, especially at the T4 to T9 levels. The upper thoracic roots course approximately 3 cm caudally before exiting the vertebral column, whereas thoracolumbar roots course approximately 7 cm.<sup>71</sup> In addition, the thoracic pedicle is positioned at the cranial half of the vertebral body. As result, the thoracic intervertebral foramen maintains a relatively high position with respect to the intervertebral disc. Furthermore, thoracic roots demonstrate the greatest distance from the superior and inferior pedicles of the intervertebral foramen.<sup>72</sup> As result, the incidence of thoracic root pain from a primary disc protrusion is less likely, due to a high neural arch and distance of the root from the disc when compared with cervical and lumbar regions.<sup>73</sup> However, when thoracic roots are irritated, root related pain could be observed in the distribution of the spinal nerve ventral rami. The 12 pairs of thoracic ventral rami are also known as intercostal nerves (with exception of the 12<sup>th</sup> ventral ramus, which is termed the subcostal nerve). These nerves innervate the pleura, costotransverse and costovertebral joints, intercostal muscles and the skin at the ventral trunk. In addition, the T1 ventral ramus also serves the brachial plexus.<sup>74</sup> Therefore, thoracic root related symptoms could be observed in regions of the anterior ribs and sternum, as well as the distributions of the posterior joints of the ribs.

### Cervical Considerations

Several distinctive anatomical features in the cervical spine lend to root-related pain. The spinal nerves course through the neural groove and then enter the intervertebral foramen, which is located anterior-medial to the ZAJ articular processes and lateral to the uncinat processes. From the foramen, the nerves course through sulci (or gutters) within the cervical transverse processes. These bony confines pre-dispose patients to arm pain that is commonly related to nerve root compression associated with degenerative changes in the uncinat and or zygapophyseal articular processes.<sup>5</sup> These degenerative changes result in a narrowing of the interverte-



bral foramen in a front-back direction versus the up-down direction frequently witnessed in the lumbar spine.<sup>75</sup> However, settling of the cranial vertebral body in response to disc degeneration can narrow the intervertebral foramen in an up-down direction. Foraminal area can decrease as much as 40% to 45% with a mere 3 mm settling of the cranial body.<sup>76</sup> Fortunately, the consequences of these compressive events can be clinically reduced through a dorso-ventral mobilization procedure applied to the caudal bony segment, as this method enhances the a-p diameter of the canal.<sup>11</sup>

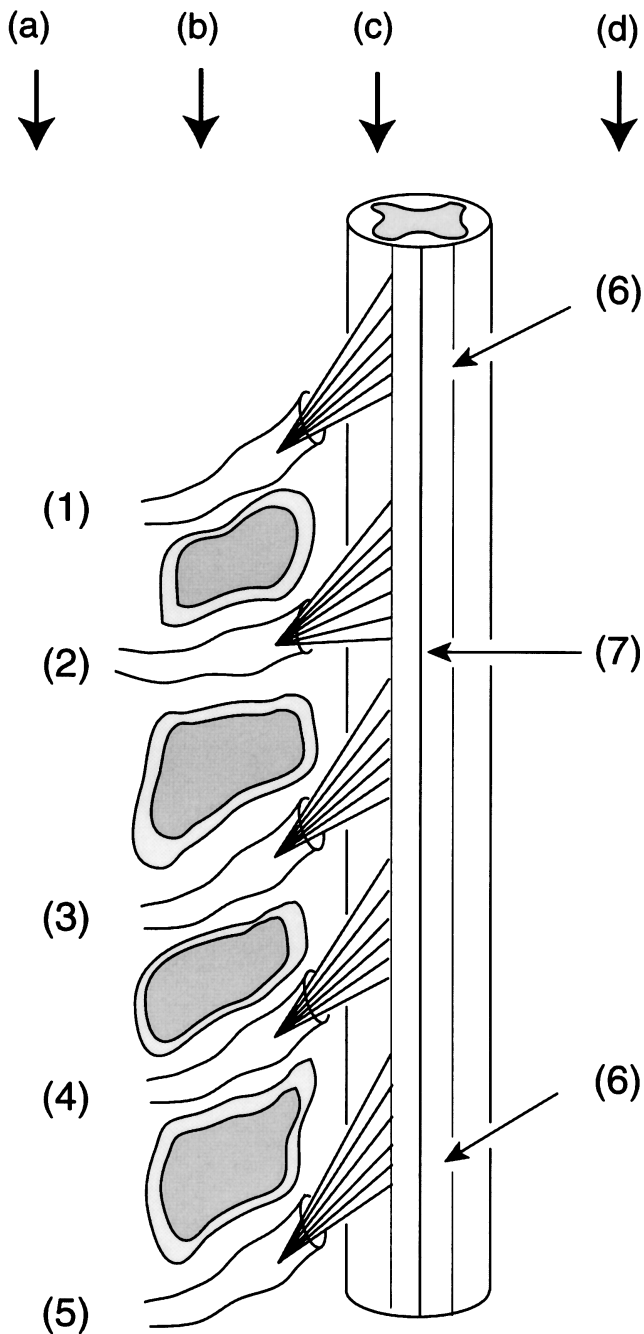
Different anatomical features lend each cervical root level to producing root-related pain. For example, the C7 root demonstrates 2 unique distinctions that lend it to a compressive event and root-related symptoms. First, it is relatively larger than the other roots in the cervical spine. Second, the root courses closer to the ZAJ articular processes versus other roots. These features may predispose the C7 root to the compressive events related to segmental degeneration.<sup>77</sup> Conversely, the antero-posterior diameter of the intervertebral foramina is smaller for the C4, C5, and C6 root levels. Furthermore, the nerve root length gradually increases from C3 to C6.<sup>78</sup> These features, in combination with higher uncinat processes and a longer course for nerve roots in close proximity of the uncovertebral and ZAJ articular processes, may predispose the C4 to C6 root levels to compression. Finally, the DRG's in the cervical spine demonstrate either an intra-foraminal or extra-foraminal variance in location.<sup>79</sup> Lu et al found that the C6 root demonstrates a 48% incidence of intra-foraminal DRG positioning, whereas the C7 root demonstrates a 27% incidence of the same phenomenon.<sup>76</sup> These patterns may predispose dorsal root ganglia of C6 and C7 to kinking around the bony architecture during movement, resulting in a sharp radicular pain in the upper extremity.

The uncinat processes may contribute to a reduced incidence of arm pain associated with a primary disc lesion. The uncinat processes serve to restrain a posterior-lateral disc protrusion or prolapse, reducing the disc's contact with the root. Furthermore, if a primary disc affliction tension-loads the root and produces arm pain, it will inevitably produce neck pain, as a disc bulge not only accesses the root medial to the uncinat process, but also irritates the highly innervated posterior longitudinal ligament that is in close proximity. Furthermore, a huge prolapse extending over the uncinat process, a neurinoma, thoracic outlet syndrome, foraminal stenosis, or serious pathology must be suspected if the patient presents with isolated arm pain.<sup>80</sup>

Each cervical root is comprised of multiple ventral and dorsal rootlets that leave the spinal cord and course to the intervertebral foramen at varying angles. Whereas the cranial rootlets traverse to the foramen in a dorsal-lateral oblique direction, the caudal rootlets of a given segment approach the foramen in a more horizontal direction (see Figure 8).<sup>81</sup> Thus, there is very little distance between the pedicle and the dural sac that contains the superior nerve roots. Conversely, the inferior nerve rootlets are approximately 1.5 mm below the superior pedicle, with the greatest distance demonstrated at C6.<sup>82</sup> In addition, C5 demonstrates the shortest roots and the most horizontal course, thus pre-disposing this neural segment to pathological tension loading after surgical fixation or disc bulge at other surrounding cervical levels.<sup>44</sup> For example, a posterior paramedian primary disc affliction at C6C7 may result in C5 radiculopathy. As this disc prolapse deviates the spinal cord contralaterally, the lateral movement first loads the horizontally oriented C5 root, potentially resulting in C5 radiculopathy. Thus, a C5 radiculopathy is not necessarily suggestive of a C4C5 disc affliction.

### Root Pathophysiology

Nerve roots require chemical irritation to become mechano-sensitive pain generators.<sup>83</sup> The ventral dural sleeve is richly innervated with "Silent" nociceptors that possess high activation thresholds.<sup>40,53,84</sup> Although normal mechanical stimuli do not activate these receptors, they can become mechanosensitive after being "sensitized" by chemical irritants such as serotonin, histamine, bradykinin, prostaglandins, and phospholipase A2 (PLA2).<sup>40</sup> This nerve root irritation can emerge from both primary and secondary disc-related disorders in the spine. McCarron et al observed a marked inflammatory response in nerve roots that were exposed to autologous nucleus pulposus.<sup>84</sup> This response was accompanied by edema, fibrin deposition, cellular infiltrates, and granular tissue formation. Eventual fat coalescence, hypervascularization and regional fibrosis developed in the region of the exposed tissue. Additionally, Olmarker et al observed a decreased nerve conduction velocity in roots that were exposed in a similar fashion.<sup>57</sup> Furthermore, Olmarker et al observed root intracellular edema and Schwann cell expansion during a similar evaluation.<sup>85</sup> Finally, Kawakami et al found that inflammatory-mediated leukocyte proliferation in the region of a root exposed to autologous nucleus pulposus resulted in marked hyperalgesia in experimental animals, thus confirming the role of inflammatory cellular infiltrates in root related pain.<sup>86</sup>



**Figure 8.** Course of the Cervical Rootlets:  
 (a) Level: (1) C4; (2) C5; (3) C6; (4) C7; (5) C8;  
 (b) Cervical Roots coursing through intervertebral forminae;  
 (c) Course of Rootlets from Spinal Cord to Dural Sleeve  
 (d) Direction of Course for most Caudal Rootlet at Selected Levels: (6) Caudal Lateral Oblique course for C4 & C8; (7) Horizontal Course for C5

Investigators have observed other effects from neural tissue exposure to autologous nuclear material. Kawakami et al detected increased concentrations of phospholipase A2 and nitric oxide in the proximity of herni-

ated nucleus pulposus and linked these concentrations to hyperalgesic radiculopathy.<sup>87</sup> Additionally, Takebayashi et al observed increased DRG hyperexcitability and mechanical hypersensitivity when the ganglion was exposed to autologous nuclear material.<sup>88</sup> These experiments illustrated the rapid, progressive, and significant chemical consequences that can result from nuclear migration associated with a primary disc affliction.

Similar findings have been observed during secondary disc-related compression of the root and DRG, linking these events to root-related pain.<sup>20</sup> Garfin et al suggested that prolonged root compression could lead to root injury and vascular ischemia, resulting in root inflammation and sustained symptoms.<sup>40</sup> Frank suggested that arachnoid cells could initiate the sustained intradural inflammatory reactions and fibrosis observed in cervical nerve roots associated with spondylotic cervical myeloradiculopathy.<sup>89</sup> In addition, macroscopic changes have been observed in the cauda equina of experimental animals following prolonged compression.<sup>20,90</sup> Prolonged stenotic compression resulted in adherence of the cauda equina, an increase in the ratio of small-diameter axons, and a reduced ratio of large-diameter axons. Furthermore, these changes appeared to be more profound when imposed on older experimental animals. As nociceptive signals are conducted across small diameter sensory axons, these neuro-plastic changes could lead to increased nociceptive afference communicated to the dorsal horn of the spinal cord.

Various investigators discovered that chronic DRG compression produces DRG ectopy, regional hyperalgesia, and subsequent neuropathic pain responses.<sup>91-94</sup> Investigators have postulated numerous mechanisms responsible for increased DRG cyclic activity. These mechanisms that produce heightened DRG electrical excitability<sup>91</sup> include ganglion cross-excitation,<sup>95</sup> vasoconstrictive events,<sup>96</sup> and altered sodium and calcium channel expression.<sup>97-99</sup> Other investigators have discovered that the DRG demonstrates increased sympathetic fiber expression after injury to neural tissue. This expression involves sympathetic collateral sprouting<sup>100-102</sup> that forms a sympathetic fiber basket around the DRG.<sup>103</sup> This basket appears to be responsible for the sympathetic-sensory coupling that triggers DRG ectopy and sympathetically maintained pain.<sup>104</sup>

### Clinical Profile of Root-Related Pain

Primary disc-related disorders are typically seen in persons under 50 years of age, with either acute (sharp) or gradual onset of symptoms (ache). The onset can be pre-

ceded by multiple episodes of low back pain (if a protrusion) and can be accompanied by leg pain that worsens in the early morning, as a function of disc imbibition during the previous night. Sitting and forward stooping increases low back and lower extremity pain, as does trunk flexion and either ipsilateral or contralateral sidebending. Imaging studies may reveal a disc lesion, but these findings are not necessarily pathognomonic for clinical primary disc disorders.<sup>105-107</sup>

Root-related pain associated with a primary disc lesion (protrusion, prolapse, or extrusion) can be radicular and non-radicular in nature. Radicular symptoms extend into a given dermatomal distribution and are initially sharp in nature, due to DRG compression. Aching pain can radiate into the buttock and lower extremity as the nerve root becomes mechanosensitive, in context with chemical irritation. Additionally, irritation of the ventral dura can produce referred, non-radicular aching pain into the low back, buttock, and proximal posterior thigh.<sup>108</sup> This distribution is typically diffused, as a function of polysegmental innervation from the sinuvertebral nerve,<sup>5</sup> and is perpetuated by fibrotic adhesions. Positive dural tests can differentiate these symptoms from the referred, non-radicular pain that is produced by degenerative internal disc disruption.<sup>109</sup>

A primary disc lesion can mechanically produce other radicular symptoms that accompany root-related pain. A posterior-lateral disc prolapse is the result of a breach in the outer annulus of the disc as result of macrotrauma. This response produces significant root tension and a true axonal compromise, potentially resulting in motor and sensory disturbances.<sup>110</sup> Conversely, protrusion demonstrates an intact outer annulus without any neurological deficits, due to the lack of true axonal involvement. Finally, posterior central prolapse is the consequence of PLL rupture and migration of nuclear material into the spinal canal. This affliction can present with cauda equina symptoms, which include bowel and bladder disturbances, saddle anesthesia, numbness in the plantar aspects of both feet and impotence in males. The presence of cauda equina symptoms merits surgical intervention.<sup>11</sup>

In secondary disc-related disorders, nerve root compression syndrome (NRCS) commonly involves a static or dynamic stenosis secondary to degenerative changes in the spine. NRCS in the lumbar spine is typically associated with lateral recess or foraminal narrowing from hypermobile segments. Clinically, lumbar NRCS is seen in persons over 50 years of age with a gradual onset of symptoms (ache) and a history of multiple episodes of

back pain. The patients typically complain of severe radiating pain during the day that keeps them up at night. During the functional examination, if the compression lies in the intervertebral foramen, trunk extension in combination with ipsilateral sidebending and rotation can provoke the lumbar root related pain, whereas Spurling's test will provoke the same in the cervical spine. Patients with NRCS commonly present with a segmental capsular pattern of limitation associated with degenerative changes that may or may not be painful. Imaging studies typically reveal disc narrowing and signs of NRCS. In the cervical spine, NRCS is most frequently associated with bony changes from the uncovertebral and zygapophyseal joints leading to anteroposterior narrowing of the intervertebral foramen. This NRCS is most frequently seen in persons over 45 years of age having multiple episodes of local cervical pain. Pain typically has a gradual onset and is worst at the end of the day accompanied by paresthesias, sensory loss, and possible motor disturbances.<sup>11</sup>

Intermittent neurogenic claudications in the lumbar spine are associated with cauda equina compression that is the consequence of spinal stenosis. Typically, symptoms occur with walking secondary to vascular engorgement and inflammatory cascade, in response to stenotic changes. Patients are commonly greater than 50 years of age and more frequently male. The patient frequently complains of a "heavy" or "tired" feeling in both lower extremities that occurs with walking and eventually forces him or her to stop and rest. At night, the patient's sleep patterns are interrupted by cramping and "restless legs" that is only alleviated with getting up and walking. There is a long history of back pain in conjunction with claudication symptoms. The patient tends to develop a Simeon or kyphotic posture with walking and is unable to stand with an erect posture. Upon examination, extension is extremely limited, whereas flexion is readily available. The straight leg raise is usually positive, whereas slump testing will be negative. Sensory and motor disturbances may be transient. Patient's can bike, walk uphill or ascend stairs with decreased symptoms (due to a flexion posture).<sup>11,25</sup>

Other medical pathologies can produce root-related pain. For example, An reported that cervical radicular pain must be differentiated from numerous neurologic and neoplastic conditions, such as multiple sclerosis, ALS, syringomyelia, neurinoma, pancoast tumors, intracerebral tumors, tumors of the shoulder girdle, and metastatic disease. In addition, the same author suggested that thoracic outlet syndrome, peripheral nerve

entrapment, primary shoulder lesions, and visceral disorders could produce symptoms similar to cervical radicular pain. The investigator suggested that a thorough clinical history and physical examination would guide the clinician in the differential diagnosis.<sup>111</sup>

Herpes zoster can produce severe root-related pain any region of the spine,<sup>112</sup> accompanied by multiple skin eruptions. This condition is caused by a reactivation of latent varicella zoster virus and can be very severe for patients who have not previously contracted chickenpox. A dermatomal pain and skin lesion pattern usually erupts secondary to spinal ganglia harboring the latent virus. Herpes zoster occurs most frequently in persons over the age of 60 years, making it difficult to differentiate from NRCS. Skin lesions can take up to 3 to 5 days to appear and eradication is difficult. The root-related pain associated with thoracic primary or secondary disc-related disorders demonstrates a similar presentation to herpes zoster. However, zoster demonstrates several clinical distinctions that are useful for differential diagnosis. First, the pain associated with herpes zoster is constant, severe and unaffected by changes in posture. Second, sensory changes are diverse and widespread when compared to single-level radiculopathy. Third, the pain and paresthesias associated with zoster may increase with temperature changes or exposure to the sun. Finally, zoster rarely induces motor loss.

### Dural Testing: Procedures and Outcomes

The root-related pain associated with primary and secondary disc-related disorders can be clinically provoked through a series of dural tests. For the lumbar spine, the clinician can incorporate different iterations of the Straight-Leg-Raise (SLR) and Slump testing. These tests can be systematically performed to exploit the mechanical behaviors of the roots and dura within the surrounding anatomical containers. The outcomes of the tests will differ for root symptoms produced by primary versus secondary disc related disorders, and the clinician can use these outcomes for differential diagnosis.

The SLR can be performed in 2 different fashions. For either sequence, the patient is positioned in supine with the head flat on the table. For SLR with a distal initiation (SLRDI; see Appendix A), the clinician first flexes the knee and hip so that the patient's heel is close to the buttock. In this position, the clinician fully dorsiflexes the ankle/foot, so to distally pre-tension the sciatic nerve tissue beyond the tension point at the popliteus.<sup>113</sup> This is performed to ensure maximal distal movement of the dura in subsequent stages of the test,

because mere positioning of the lower extremity flat on the table without this maneuver could induce a proximal movement of the distal sciatic nerve towards the popliteus.<sup>1</sup> From this position, the clinician returns the lower extremity to an extended position on the table, while maintaining the dorsiflexed ankle/foot. Then the leg is raised by passively flexing the hip, while maintaining knee extension and ankle/foot dorsiflexion. During this motion, tension is accrued and the dura moves distally. The motion is continued until either the movement reaches the end range or when the patient's symptoms are reproduced. Next, the clinician asks the patient to raise his or her head with a chin tuck, thus flexing the cervical spine. In this position, the tension incurred by this test sequence will be maximized within the entire neural system. Finally, the clinician releases the dorsiflexion in the ankle/foot, thus reducing tension and allowing the dura to move cephalad back towards the original starting position.

For SLR with a proximal initiation (SLRPI; see Appendix B), the clinician first flexes the knee and hip so that the patient's heel is close to the buttock. Once again, this places the lumbosacral dura in a slackened position. Next, the clinician asks the patient to raise the head from the mat with a chin tuck, thus flexing the neck and potentially pre-tensioning, to a limited extent, the lumbosacral plexus.<sup>61</sup> Subsequently, the clinician returns the lower extremity to an extended position on the mat, while maintaining the dorsiflexed ankle/foot. Then the leg is raised by passively flexing the hip, while maintaining knee extension and ankle/foot dorsiflexion. During this motion, tension is maximally accrued; however, the distal dura movement is limited by the cephalad pre-tensioning of the lumbosacral dura. Finally, the clinician allows the patient to return the head back to the mat, thus reducing any cephalad pre-tensioning and allowing the dura to move distally.

The Slump test series can be divided into a Slump with proximal initiation (SPI) and Slump with distal initiation (SDI). For the starting position in either test, the clinician asks the patient to sit erect with the patient's knees flexed to 90° and the legs hanging off of the side of the examination table (see Appendix C). For the SDI, the clinician first dorsiflexes the ankle/foot, so to distally pre-tension the sciatic nervous tissue distal to the popliteal anchor point. While maintaining this position, the clinician moves the dura distal and lateral with respect to the surrounding container by passively extending the knee. Second, entire dural system is maximally tension loaded as the patient tucks the chin, forward flexes the

neck and slumps the trunk forward, while maintaining a vertical lumbar position. Finally, the clinician releases the ankle/foot dorsiflexion, thus reducing dural tension and allowing the dural structures to move back to their starting position.

The SPI is performed with a reversed sequence. First, the patient tucks the chin so the neck will be positioned in full flexion. As previously mentioned, this position moves the lumbar plexus and pre-tensions the sacral plexus in a cephalad. Then, the clinician passively dorsiflexes the patient's ankle/foot, while keeping the lumbar spine in the vertical plane. While holding the ankle/foot in dorsiflexion, the clinician passively extends the knee. This position imposes maximum tension in the entire neural system from cephalad to caudad (distal). However, the lumbosacral dura cannot actually move distally, due to the cephalad pre-tensioning. Finally, the patient raises the head and neck into extension, while maintaining the slump position. This consequently reduces the previously imposed cephalad tension load on the dura, finally allowing it to move distally and laterally with respect to the surrounding container (see Appendix D).

For the thoracic spine, root tension can be maximized while utilizing a modified slump test in long sitting. The thoracic slump testing sequence is similar to the lumbar procedures, with the addition of end-range axial rotation in the pre-positioning. Proximal and distal initiation can again be performed in rotation towards or away from the side of pain.<sup>11</sup> Conversely, similar procedures are not reliable for the examination of cervical spine root-related pain, due to the previously mentioned cervical root anchors.<sup>44</sup> Rather, the cervical roots require cervical flexion plus scapular retraction in order to effectively tension load the dura. Dural tension can be achieved through a traction load between the T1 root and the anchoring at the lower cervical dural root sleeves. In addition, changes in cervical root-related symptoms can be witnessed when glenohumeral abduction is added during a pain-provoking cervical lateral flexion. Here, shoulder abduction reduces dural tension through brachial plexus movement and symptoms consequently decline.

Investigators have demonstrated high intertester reliability with selected dural tests.<sup>114–116</sup> Other investigators have utilized dural tests for diagnostic classification of lumbosacral disorders<sup>117</sup> and determination of candidacy for selected management procedures.<sup>118</sup> However, certain factors may influence test utility. Cameron et al demonstrated that pelvis and contralateral hip positions would significantly influence SLR range values.<sup>119</sup> In addition, Hall et al found that a pre-position of lumbar

flexion significantly reduced SLR range.<sup>115</sup> Johnson and Chiarello demonstrated a significantly reduced knee extension angle during the Slump test when the patient was initially pre-positioned in either cervical flexion or ankle dorsiflexion.<sup>120</sup> Although this investigation reflected the potential impact of these pre-positions on neural mobility, one may question the role of hamstring activity in the reduction of range. Lew and Briggs addressed this dilemma when they observed a significant reduction of knee extension during the cervical flexion pre-position of the Slump test, accompanied by a lack of significant differences in hamstring electromyographic activity.<sup>121</sup> In summary, these outcomes reflect the importance of systematic inter-tester and intra-tester consistency when administering dural tests.

A positive dural test may include a reduction of the joint range produced in the test movement. However, as previously demonstrated, range of motion may vary in response to other factors. In addition, simple discomfort does not necessarily constitute a positive test, as normal subjects may experience this during test procedures.<sup>1,121</sup> Thus, an important criterion that constitutes a positive dural test is a change in the patient's actual symptoms during the test procedure. If the patient presents with radicular or nonradicular pain, then the clinician should expect the patient to experience the same (or similar) symptoms during a positive dural test.

As previously mentioned, the dura can be irritated by the tension loading encumbered during a primary disc-related disorder. This is a consequence of the dura being intimately attached to the disc at the posterolateral corners of the annulus in a vulnerable area of the endplate.<sup>8–11,122</sup> The lower lumbar and cervical disc segments are more prone to develop intradural disc lesions secondary to the adhesive arrangement between the PLL and ventral dura, whereby a nucleus pulposus could tension load the annulus, PLL, and dura as if one structure.<sup>15,123</sup> In the event that the disc lesion is large enough to tension load an adjacent nerve root, the patient may experience lower extremity pain. Additionally, pain will be provoked during the slump and straight leg raise tests, especially when the root tension is greatest (ankle/foot dorsiflexed, knee extended, and chin tucked; see Table 1). Furthermore, the patient will experience greater symptom provocation with slump versus straight leg raise, due to increased root tension and increased posterior nuclear migration during the slump position.

Far lateral primary disc lesions produce intense and severe radicular pain, particularly in upper lumbar

**Table 1. Dural Test Outcomes**

Test	Provocation Outcomes		
	Primary Disc	Latent Primary or Secondary	Secondary Disc
	Protrusion, Prolapse or Extrusion	Epidural Adhesions	Nerve Root Compression Syndrome or INC**
	Root Tension Event	Root Mobility Event	Root Compression Event
Straight Leg Raise Distal Initiation (SLRDI)			
Ankle DorsiFlexion + SLR	Mild Pain (+)	Moderate Pain (++)*	Moderate Pain (++)*
Chin Tuck + Neck Flexion	Pain Increases (++)*	Pain Decreases	Pain Decreases
Ankle PlantarFlexion	Pain Decreases	(-) Pain	(-) Pain
Straight Leg Raise Proximal Initiation (SLRPI)			
Chin Tuck + Neck Flexion	(-) Pain	(-) Pain	(-) Pain
Ankle DorsiFlexion + SLR	Pain Increases (++)*	(-) Pain	(-) Pain
Return Head to Mat	Pain Decreases	Pain Increases (++)*	Pain Increases (++)*
Slump Distal Initiation (SDI)			
Ankle DorsiFlexion + Knee Extension	Moderate Pain (++)	Moderate Pain (++)*	(-) Pain
Chin Tuck, Neck Flexion, Trunk Slump	Pain Increases (+++)*	Pain Decreases	(-) Pain
Ankle PlantarFlexion	Pain Decreases	(-) Pain	(-) Pain
Slump Proximal Initiation (SPI)			
Chin Tuck, Neck Flexion, Trunk Slump	Mild Pain (+)	(-) Pain	(-) Pain
Ankle DorsiFlexion + Knee Extension	Pain Increases (+++)*	(-) Pain	(-) Pain
Neck Extension + Raise Head	Pain Decreases	Pain Increases (++)*	(-) Pain

(+) = Minimal Pain

(++) = Moderate Pain

(++) = Severe Pain

\*Indicates greatest pain during the test sequence

\*\*Intermittent Neurogenic Claudications

roots, with an incidence of approximately 6% to 10%. The intense, immediate pain is related to immediate pressure against a mechanosensitive DRG. Additionally, far lateral disc lesions involve the roots that exit at the same level as the disc lesion. This event contrasts the posterolateral disc lesion that affects the root level below the affected disc. Because far lateral disc protrusions occur more frequently in the upper lumbar segments, the femoral nerve tension test is most provocative.<sup>22</sup>

Root-related symptoms can be produced by secondary disc-related changes in the surrounding lumbar container. As a consequence, patients with INC or NRCS may demonstrate positive dural tests, albeit they are quite different from the outcomes witnessed with primary disc related disorders. Provocation will be related to either to a compression of a root's inflammatory focus or a loss of dural sleeve mobility associated with fibrosis. In either case, the provocation will be directional. For instance, if the patient suffers from compression of an irritated root between a degenerative disc bulge (anteriorly) and ligamentum flavum (posteriorly), then pain will increase with caudad (distal) dural movement and will decrease with cephalad (proximal) movement. Here, distal dural movement translates the root's irritable focus through the narrowed path between the disc and ligamentum flavum or articular process, whereas cephalad

(proximal) movement reduces the compression and subsequent symptoms. This test response is witnessed during the SLR procedures but is frequently absent during Slump procedures, due to the increased area of the intervertebral foramen produced in a slump position (see Table 1).<sup>124</sup>

Similar directional dural test outcomes can be witnessed when the patient suffers from dural sleeve fibrotic adhesions. Once again, distal dural movement increases symptoms and cephalad (proximal) movement reduces them. However, unlike the inflammatory pattern previously mentioned, this provocation pattern is not revoked in the Slump position. Rather, the same directional provocation will be repeated, due to the constraint by fibrotic adhesions on dural sleeve mobility, regardless of intervertebral foraminal diameter (see Table 1).

Root-related pain associated with secondary disc degenerative changes can be provoked in the cervical spine. The most painful test eliciting arm symptoms will be the modified Spurling test. For this test, the patient's head and neck is placed in extension, coupled with sidebending and rotation towards the side of arm pain. Here, the clinician stabilizes patient's the opposite shoulder with one hand and provides axial compression to the head and neck with the other. Although the symptoms may be quickly provoked, the clinician may be required to

hold the modified Spurling position for up to 2 minutes, so to allow sufficient time for the gradual onset of symptoms.<sup>125</sup>

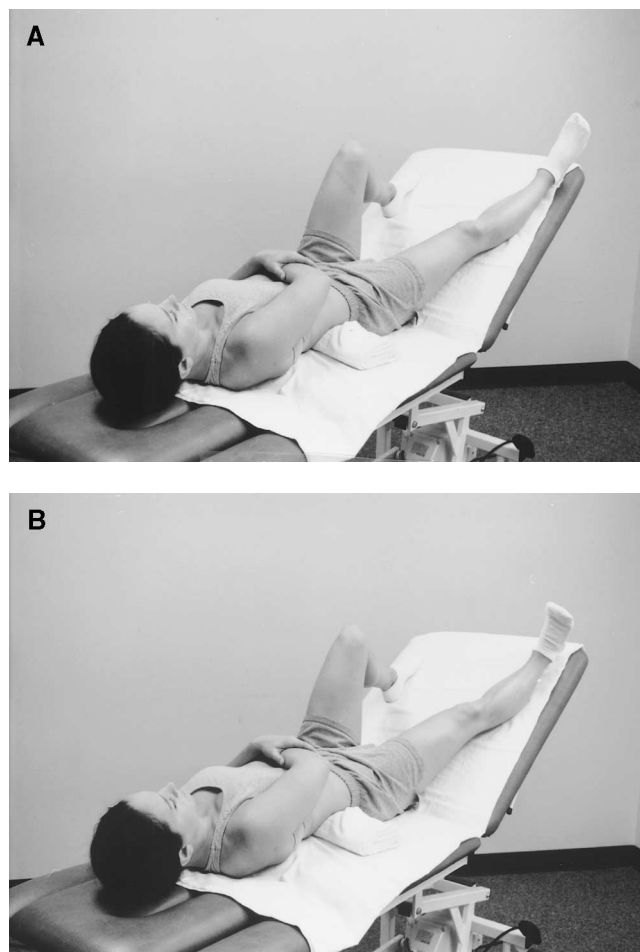
### Conservative Management

Conservative measures can serve as a valuable concomitant to invasive pain management procedures that are aimed at reducing inflammation about a nerve root, reducing epidural adhesions, and controlling sympathetic activity associated with neurogenic root-related pain. Conservative management of the root-related pain associated with a primary disc-related disorder can involve activity counseling, local modalities, traction, 3-dimensional (3-D) axial separation, extension exercises (in some cases), stabilization exercises, and generalized cardiovascular conditioning (activation). Activity counseling is crucial to the patient suffering from this condition. Indahl et al suggested that including information regarding the nature of the problem would help reduce patients' fear and give them a reason to resume activity.<sup>126</sup> Patients are counseled to avoid sitting and bending during the first few hours of the morning, as this position could increase root tension associated with diurnal stress fluctuations and increased disc height.<sup>127</sup> Local modalities can be used as a precursor to other interventions, so to relax the patient through convergence in the dorsal horn of the spinal cord.

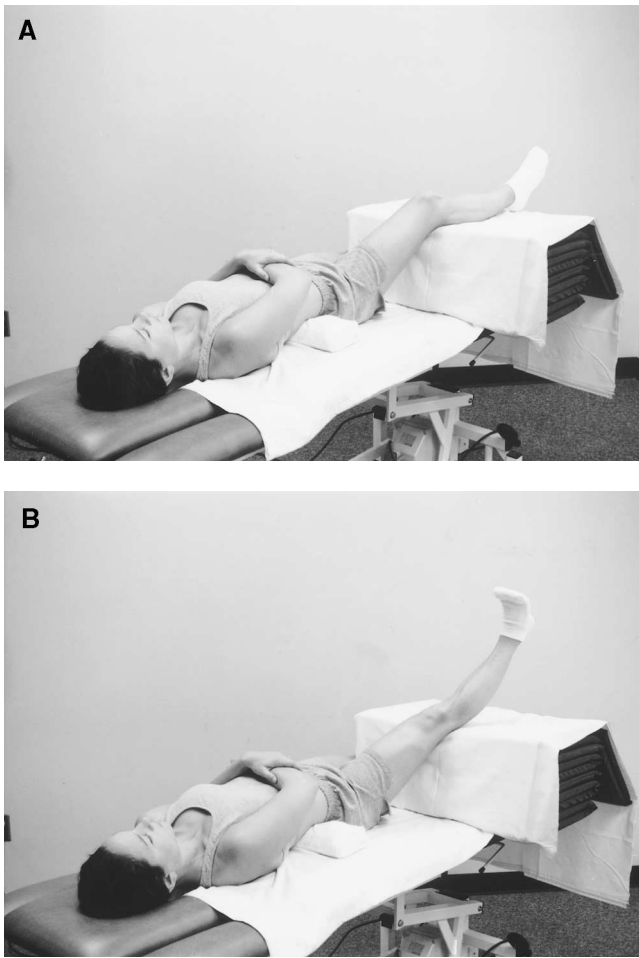
Static lumbar traction may be of benefit with certain cases if implemented within the first six weeks post-onset.<sup>7</sup> Investigators have demonstrated several positive effects associated with the application of traction to individuals with primary disc related disorders. Investigators have demonstrated that traction produces (1) reduced disc protrusion,<sup>128-130</sup> (2) reduced motor function impairment associated with radiculopathy,<sup>131</sup> and (3) reduced sequelae associated with dural testing.<sup>132</sup> For lumbar traction, Winkel et al recommend at least 30 minutes of static traction adjusted to 25% to 50% of the patient's body weight, along with a thoracic stabilization belt. For cervical traction, the same author recommends a manual technique that utilizes prepositioning in cervical rotation and or sidebending.

In addition to traction, a clinician could implement 3-D axial separation for lumbar root related pain associated with a primary disc lesion that bulges medial to the nerve root.<sup>11,133</sup> This technique is preferred over axial traction for the medial bulge, as traction could increase the tension loading of the root around the protrusion or prolapse and subsequently escalate the patient's symptoms. In concert with traction or 3-D axial separation, a clinician could

ask the patient to perform active extension in standing, as well as prone press-ups. These exercises have been used to encourage symptoms to centralize, or relocate from a distal site proximally toward the midline.<sup>134</sup> Investigators have suggested that observing for symptom centralization reduces the need for expensive diagnostic procedures based on the value of the behavior for discriminating between discogenic and non-discogenic pain.<sup>134</sup> In addition, investigators have suggested that clinicians can expect centralizing patients to experience greater improvements in functional outcomes versus noncentralizers<sup>135,136</sup> and that further diagnostic studies are warranted when patients do not centralize after a limited number of visits.<sup>135</sup> However, the mechanism underlying the centralization phenomenon remains controversial and it is the view of these authors that the phenomenon is related, at least in part, to reduced tension imposed on the nerve root with



**Figure 9.** Neural Flossing, Phase 1. (a) Starting Position; (b) Finishing Position.



**Figure 10.** Neural Flossing, Phase 2: (a) Starting Position; (b) Finishing Position.

mechanical maneuvers (such as extension), versus simple migration of nuclear material.

As previously noted, patients who suffer from central and lateral root compression may demonstrate directional dural test outcomes during the SLR procedures. These cases may benefit from intermittent traction to encourage “rinsing” of the venous plexus. In addition, patients can be encouraged to engage in neural flossing, whereby they perform repetitive, slow, rhythmic nonpainful distal initiation of dural movements. For the procedure, the patient is passively positioned supine in slight supported lordosis with the hip slightly abducted and externally rotated, as well as flexed between 30° and 60°. This position can be achieved by positioning a soft chair under the distal lower extremity. After positioning, the patient performs repetitive ankle/foot dorsiflexion for 100 to 150 repetitions once or twice daily. The activity can be progressed to repetitive terminal knee extension with

the knee starting in a supported, flexed position (see Figures 9 & 10).

Similar neural flossing procedures can be used with patients who suffer from neural mobility limitations with directional dural test outcomes during both SLR and Slump procedures. Additionally, flossing can be eventually implemented with patients who suffer from root related pain associated with a primary disc-related disorder, so to reduce the risk of dural adhesions and potentially decrease any inflammatory response in the nerve root. Finally, similar flossing procedures can be implemented in the upper extremity for afflictions related to the cervical spine, but results may be limited as a function of the previously mentioned root anchors.

Various injection applications have been described that effectively address chemically mediated and/or fibrotic nerve root afflictions. These are often needed in conjunction with the conservative techniques described above. Although the descriptions of these techniques are beyond the scope of this article, the reader can refer to appropriate authors for the details of those procedures and their expected outcomes.<sup>137–141</sup>

### Summary

Distinctions in the patho-anatomy, biomechanics and pathophysiology of spinal nerve roots appear to contribute to the pathology, diagnosis, and management of root-related pain. Primary disc related disorders could produce root-related pain when tension is imposed on a mechanosensitive root, resulting in local transverse root compression and subsequent symptoms. Conversely, secondary disc-related degeneration can produce compression on the nerve roots, resulting in chemical and mechanical consequences imposed on the nervous tissue within the spinal canal, lateral recess, intervertebral foramina, and extraforminal regions. Finally, root mobility can be limited by latent dural adhesions, leading to root irritation. Appropriate differentiation between the tension, compression and adhesive events that are imposed on a painful root will guide a clinician in the selection of suitable management strategies. Differences in root-related pathology can be observed between lumbar, thoracic, and cervical spinal levels, meriting the implementation of different diagnostic tools and management options.

### REFERENCES

1. Butler DS. *The Sensitive Nervous System*. Adelaide, Australia: Noigroup Publications; 2000.



2. Ursu TR, Porter RW, Navaratnam V. Development of the lumbar and sacral vertebral canal in utero. *Spine*. 1996;21:2705–2708.
3. Ebraheim NA, Xu R, Darwich M, Yeasting RA. Anatomic relations between the lumbar pedicle and the adjacent neural structures. *Spine*. 1997;15;22:2338–2341.
4. Wiltse LL, Berger PE, McCulloch JA. A system for reporting the size and location of lesions of the spine. *Spine*. 1997;22:1534–1537.
5. Bogduk N. *Clinical Anatomy of the Lumbar Spine and Sacrum*. New York, NY: Churchill Livingstone; 1997.
6. Adams MA. Biomechanics of the intervertebral disc, vertebra, and ligaments. In: Szpalski M, Gunzburg R, Pope MH, eds. *Lumbar Segmental Instability*. Philadelphia, Pa: Lippincott Williams & Wilkins; 1999:3–13.
7. Sizer PS, Phelps V, Matthijs O. Pain generators of the lumbar spine. *Pain Prac*. 2001;3:255–273.
8. Hogan Q, Toth J. Anatomy of soft tissues of the spinal canal. *Reg Anesth Pain Med*. 1999;24:303–310.
9. Kallakuri S, Cavanaugh JM, Blagoev DC. An immunohistochemical study of innervation of lumbar spinal dura and longitudinal ligaments. *Spine*. 1998;23:403–411.
10. Wiltse LL. Anatomy of the extradural compartments of the lumbar spinal canal. Peridural membrane and circumneural sheath. *Radiol Clin North Am*. 2000;38:1177–1206.
11. Winkel D, Aufdemkampe G, Matthijs O, Meijer OG, Phelps V. *Diagnosis and Treatment of the Spine: Nonoperative Orthopaedic Medicine and Manual Therapy*. Gaithersburg, Co: Aspen Publishers, Inc; 1996.
12. Scapillini R. Anatomic and radiologic studies on the lumbosacral meningovertbral ligaments of humans. *J Spinal Disord*. 1990;3:6–15.
13. Beel JA, Stodieck LS, Luttges MW. Structural properties of spinal nerve roots: Biomechanics. *Exp Neurol*. 1986;91:30–40.
14. Kumar R, Berger RJ, Dunsker SB, Keller JT. Innervation of the spinal dura: myth or reality? *Spine*. 1996;21:18–26.
15. Blikra G. Intradural herniated lumbar disc. *J Neurosurg*. 1969;31:676–679.
16. Parke WW, Watanabe R. Adhesions of the ventral lumbar dura: an adjunct source of discogenic pain? *Spine*. 1990;15:298–303.
17. LaBan MM, Wilkins JC, Wesolowski DP, Bergeon B, Szappanyos BJ. Paravertebral venous plexus distention (Barton's): an inciting etiologic agent in lumbar radiculopathy as observed by venous angiography. *Am J Phys Med Rehabil*. 2001;80:129–133.
18. Wiltse LL, Fonesca As, Amster J, Dimartino P, Ravessoud FA. Relationship of the dura, Hofmann's ligaments, Barton's plexus, and a fibrovascular membrane lying on the posterior surface of the vertebral bodies and attaching to the deep layer of the posterior longitudinal ligament: an anatomical, radiologic, and clinical study. *Spine*. 1993;18:1030–1043.
19. Takahashi K, Kagechika K, Takino T, Matsui T, Miyazaki T, Shima I. Changes in epidural pressure during walking in patients with lumbar spinal stenosis. *Spine*. 1995;20:2746–2749.
20. Yamaguchi K, Murakami M, Takahashi K, Moriya H, Tatsuoka H, Chiba T. Behavioral and morphologic studies of the chronically compressed cauda equina: experimental model of lumbar spinal stenosis in the rat. *Spine*. 1999;24:845–851.
21. Porter RW, Ward D. Cauda equina dysfunction: the significance of multiple level pathology. *Spine*. 1992;17:9–15.
22. O'Hara JJ, Marshall RW. Far lateral lumbar disc herniation: the key to intertransverse approach. *J Bone Joint Surg*. 1997;79-B:943–947.
23. Maher CO, Henderson FC. Lateral exit-zone stenosis and lumbar radiculopathy. *J Neurosurg*. 1999;90:52–58.
24. Willen J, Danielson B, Gaultz A, Niklason T, Schonstrom N, Hansson T. Dynamic effects on the lumbar spinal canal. *Spine*. 1997;22:2968–2976.
25. Sizer P, Matthijs O, Phelps V. Influence of Age on the development of pathology. *Curr Rev Pain*. 2000;4:362–373.
26. Vandenabeele F, Creemers J, Lambrechts I. Ultrastructure of the human spinal arachnoid mater and dura mater. *J Anat*. 1996;189:417–430.
27. Reina MA, Dittmann M, Lopez GA, van Zundert A. New perspectives in the microscopic structure of human dura mater in the dorsolumbar region. *Reg Anesth*. 1997;22:161–166.
28. Patin DJ, Eckstein EC, Harum K, Pallares VS. Anatomic and biomechanical properties of human lumbar dura mater. *Anesth Analg*. 1993;76:535–540.
29. Runza M, Pietrabizza R, Mantero S, Albani A, Quaglini V, Contro R. Lumbar dural mater biomechanics: Experimental characterization and scanning electron microscopy observations. *Anesth Analg*. 1999;88:1317–1321.
30. Nagakawa H, Mikawa Y, Watanabe R. Elastin in the human posterior longitudinal ligament and spinal dura. A histologic and biochemical study. *Spine*. 1994;19:2164–2169.
31. Hack GD, Koritzer RT, Robinson WL, Hallgren RC, Greenman PE. Anatomic relation between the rectus capitis posterior minor muscle and the dura mater. *Spine*. 1995;20:2484–2486.
32. Rutten HP, Szpak K, van Mameren H, Ten HJ, de Jong JC. Anatomic relation between the rectus capitis posterior minor muscle and the dura mater. *Spine*. 1997;22:924–926.
33. Groen GJ, Baijet B, Drukker J. The innervation of the spinal dura mater: anatomy and clinical implications. *Acta Neurochir*. 1988;92:39–46.
34. Konnai Y, Honda T, Sekiguchi Y, Kikuchi S, Sugiura Y. Sensory innervation of the lumbar dura mater passing through the sympathetic trunk in rats. *Spine*. 2000;25:776–782.
35. Kuslich SD, Ulstrom CL, Michael CJ. The tissue origin of low back pain and sciatica: a report of pain response to tissue stimulation during operations on the lumbar spine using local anesthesia. *Orthop Clin North Am*. 1991;22:181–187.
36. Parke WW, Watanabe R. Adhesions of the ventral lumbar dura. *Spine*. 1990;15:300–303.

37. Wilson DA, Prince JR. John Caffey award. MR imaging determination of the location of the normal conus medullaris throughout childhood. *Am J Roentgenol*. 1989;152:1029–1032.
38. Saifuddin A, Burnett SJ, White J. The variation of position of the conus medullaris in an adult population. *Spine*. 1998;23:1452–1456.
39. Cohen MS, Wall EJ, Kerber CW, Abitbol JJ, Garfin SR. The anatomy of the cauda equina on CT scans and MRI. *J Bone Joint Surg [Br]*. 1991;73-B:381–384.
40. Garfin SR, Rydevik B, Lind B, Massie J. Spinal nerve root compression. *Spine*. 1995;20:1810–1820.
41. Wall EJ, Cohen MS, Massie JB, Rydevik B, Garfin SR. Cauda equina anatomy I: Intrathecal nerve root organization. *Spine*. 1990;15:1244–1247.
42. Cohen MS, Wall EJ, Brown RA, Rydevik B, Garfin SR. Cauda Equina Anatomy II: Extrathecal nerve roots and dorsal root ganglia. *Spine*. 1990;15:1248–1251.
43. Hoy K, Hansenn ES, He SZ, Soballe K, Henriksen TB, Kjolseth D, Hjortdal V, Bunger C. Regional blood flow, plasma volume and vascular permeability in the spinal cord, the dural sac, and lumbar nerve roots. *Spine*. 1994;15:2804–2811.
44. Alleyne CH, Cawley CM, Barrow DL, Bonner GD. Microsurgical anatomy of the dorsal cervical nerve roots and the cervical dorsal root ganglion/ventral root complexes. *Surg Neurol*. 1998;50:213–218.
45. Cavanaugh JM, Yamashita T, Ozaktay AC, King AI. An inflammation model of low back pain. *Proceedings of the International Society for the Study of the Lumbar Spine*. Boston, Mass: International Society for the Study of the Lumbar Spine; 1990:46.
46. Pettersson CA. Sheaths of the spinal nerve roots. Permeability and structural characteristics of dorsal and ventral spinal nerve roots of the rat. *Acta Neuropathol*. 1993;85:129–137.
47. Yoshizawa H, Kobayashi S, Hachiya Y. Blood supply of nerve roots and dorsal root ganglia. *Orthop Clin North Am*. 1991;22:195–211.
48. Corneford M, Olmarker K, Farley DB, Weinstein JN, Rydevik B. Neuropeptide changes in compressed nerve roots. *Spine*. 1995;20:670–673.
49. Ohmori K, Kanamori M, Kawaguchi Y, Ishihara H, Kimura T. Clinical features of extraforaminal lumbar disc herniation based on the radiographic location of the dorsal root ganglion. *Spine*. 2001;26:662–666.
50. Kikuchi S, Sato K, Konno S, Hasue M. Anatomic and radiographic study of dorsal root ganglia. *Spine*. 1994;19:6–11.
51. Sato K, Kikuchi S. An anatomic study of foraminal nerve root lesions in the lumbar spine. *Spine*. 1993;18:2246–2251.
52. Hanai F, Matsui N, Hongo N. Changes in responses of wide dynamic range neurons in the spinal dorsal horn after dorsal root or dorsal root ganglion compression. *Spine*. 1996;21:1408–1414.
53. Howe JF, Calvin WH, Loeser JD. Impulses reflected from dorsal root ganglia and from focal nerve injuries. *Brain Res*. 1976;116:139–144.
54. Wall PD, Devor M. Sensory afferent impulses originate from dorsal root ganglia as well as from the periphery in normal and nerve injured rats. *Pain*. 1983;321–339.
55. Weinstein JM. Mechanism of spinal pain: the dorsal root ganglion and its role as a mediator of low back pain. *Spine*. 1986;11:999–1001.
56. Howe JF, Loeser JD, Calvin WH. Mechanosensitivity of dorsal root ganglia and chronically injured axons: A physiological basis for the radicular pain of nerve root compression. *Pain*. 1977;3:25–41.
57. Olmarker K, Rydevik B, Nordborg C. Autologous nucleus pulposus induces neuro-physiological and histological changes in porcine cauda equina nerve roots. *Spine*. 1993;18:1425–1432.
58. Synderland S, Bradley KC. Stress-strain phenomena in human spinal nerve roots. *Brain*. 1961;84:120–124.
59. Smith SA, Massie JB, Chesnut R, Garfin SR. Straight leg raising: anatomical effects on the spinal nerve root without and with fusion. *Spine*. 1993;18,8:992–999.
60. Sunderland S. Mechanisms of cervical nerve root avulsion injuries of the neck and shoulder. *J Neurosurg*. 1974;41:705.
61. Lew PC, Morrow CJ, Lew AM. The effect of neck and leg flexion and their sequence on the lumbar spinal cord. Implications in low back pain and sciatica. *Spine*. 1994;19:2421–2424.
62. Yuan Q, Dougherty L, Margulies SS. In vivo human spinal cord deformation and displacement in flexion. *Spine*. 1998;23:1677–1683.
63. Brieg A, Marions O. Biomechanics of the lumbosacral nerve roots. *Acta Radiol*. 1963;1:1141–1160.
64. Schnebel BE, Watkins RG, Dillin W. The role of spinal flexion and extension in changing nerve root compression in disc herniations. *Spine*. 1989;14:835–837.
65. Rydevik BL. Etiology of sciatica. In: Weinstein JN, Wiesel SW, eds. *The Lumbar Spine*. Philadelphia, Pa: W.B. Saunders Company; 1990:102–109.
66. Kwan MK, Woo SL-Y. Biomechanical properties of peripheral nerve. In: Gelberman RH, ed. *Operative Nerve Repair and Reconstruction*. Philadelphia, Pa: J.B. Lippincott Co; 1991:47–54.
67. Olmarker K. The spinal nerve roots. *Acta Orthop Scand*. 1991;242(Suppl):1–23.
68. Smyth MJ, Wright V. Sciatica and the intervertebral disc: an experimental study. *J Bone and Joint Surg*. 1958;40A:1401–1418.
69. Spencer DL. Mechanisms of nerve root compression due to a herniated disc. In: Weinstein JN, Wiesel SW, eds. *The Lumbar Spine*. Philadelphia, Pa: W.B. Saunders Company; 1990:141–145.
70. Saal JS. The role of inflammation in lumbar pain. *Spine*. 1995;20:1821–1827.

71. Grieve GP. *Modern Manual Therapy of the Vertebral Column*. 2nd ed. New York, NY: Churchill Livingstone; 1986.
72. Ebraheim NA, Jabaty G, Xu R, Yeasting RA. Anatomic relations of the thoracic pedicle to the adjacent neural structures. *Spine*. 1997;22:1553–1556.
73. Stone JL, Lichtor T, Bnerjee S. Intradural thoracic disc herniation. *Spine*. 1994;19:1281–1284.
74. McGuckin N. The T4 syndrome. In: Grieve GP. *Modern Manual Therapy of the Vertebral Column*. 2nd ed. New York, NY: Churchill Livingstone; 1986:370–376.
75. Ebraheim NA, An HS, Xu RM, Ahmad M, Yeasting RA. The quantitative anatomy of the cervical nerve root groove and the intervertebral foramen. *Spine*. 1996;21:1619–1623.
76. Lu J, Ebraheim NA, Huntoon M, Haman SP. Cervical intervertebral disc space narrowing and size of intervertebral foramina. *Clin Orthop Rel Res*. 2000;370:259–264.
77. Ebraheim NA, Xu R, Stanescu S, Yeasting RA. Anatomical relationship of the cervical nerves to the lateral masses. *Am J Orthop*. 1999;28:39–42.
78. Ebraheim NA, Lu J, Biyani A, Brown JA, Yeasting RA. Anatomic considerations for uncovertebral involvement in cervical spondylosis. *Clin Orthop Rel Res*. 1997;334:200–206.
79. Yabuki S, Kikuchi S. Positions of dorsal root ganglia in the cervicospine: an anatomic and clinical study. *Spine*. 1996;21:1513–1517.
80. Manifold SG, McCann PD. Cervical radiculitis and shoulder disorders. *Clin Orth Rel Res*. 1999;368:105–113.
81. Shinomiya K, Okawa A, Nakao K, Mochida K, Haro H, Sato T, Heima S. Morphology of C5 ventral nerve rootlets as part of dissociated motor loss of deltoid muscle. *Spine*. 1994;19:2501–2504.
82. Xu R, Kang A, Ebraheim NA, Yeasting RA. Anatomic relation between the cervical pedicle and the adjacent neural structures. *Spine*. 1999;24:451–454.
83. McCarter GC, Reichling DB, Levine JD. Mechanical transduction by rat dorsal root ganglion neurons in vitro. *Neurosci Lett*. 1999;273:179–183.
84. McCarron RF, Winjed MW, Hudgins PG, Laros GS. The inflammatory effect of nucleus pulposus: A possible element in the pathogenesis of low back pain. *Spine*. 1987;12:760–764.
85. Olmarker K, Stromberg J, Blomquist J, Zachrisson P, Nannmark U, Nordborg C, Rydevik B. Chondroitinase ABC (pharmaceutical grade) for chemonucleolysis. *Spine*. 1996;21:1952–1956.
86. Kawakami M, Tamaki T, Matsumoto T, Kuribayashi K, Takenaka T, Shinzaki M. Role of leukocytes in radicular pain secondary to herniated nucleus pulposus. *Clin Orthop*. 2000;376:268–277.
87. Kawakami M, Tamaki T, Hashizume H, Weinstein JN, Meller ST. The role of phospholipase A2 and nitric oxide in pain-related behavior produced by an allograft of intervertebral disc material to the sciatic nerve of the rat. *Spine*. 1997;22:1074–1079.
88. Takebahashi T, Cavanaugh JM, Cuneyt Ozaktay A, Kallakuri S, Chen C. Effect of nucleus pulposus on the neural activity of dorsal root ganglion. *Spine*. 2001;26:940–945.
89. Frank E. HLA-DR expression on arachnoid cells. A role in the fibrotic inflammation surrounding nerve roots in spondylotic cervical myelopathy. *Spine*. 1995;20:2093–2096.
90. Toh E, Mochida J. Histologic analysis of lumbosacral nerve roots after compression in young and aged rabbits. *Spine*. 1997;22:721–726.
91. Liu CN, Wall PD, Ben-Dor E, Michealis M, Amir R, Devor M. Tactile allodynia in the absence of C-fiber activation: altered firing properties of DRG neurons following spinal nerve injury. *Pain*. 2000;85:503–521.
92. Song XJ, Hu SJ, Greenquist KW, Zhang JM, LaMotte RH. Mechanical and thermal hyperalgesia and ectopic neuronal discharge after chronic compression of dorsal root ganglion. *J Neurophysiol*. 1999;82:3347–3358.
93. Xie Y, Shang J, Petersen M, LaMotte RH. Functional changes in dorsal root ganglion cells after chronic nerve constriction in the rat. *J Neurophysiol*. 1995;73:1811–1820.
94. Zhang JM, Song XJ, LaMotte RH. Enhanced excitability of sensory neurons in rats with cutaneous hyperalgesia produced by chronic compression of the dorsal root ganglion. *J Neurophysiol*. 1999;82:3359–3366.
95. Devor M, Wall PD. Cross-excitation in dorsal root ganglia of nerve-injured and intact rats. *J Neurophysiol*. 1990;64:1733–1746.
96. Habler J, Eschenfelder S, Liu XG, Janig. Sympathetic-sensory coupling after L5 spinal nerve lesion in the rat and its relation to changes in dorsal root ganglion blood flow. *Pain*. 2000;87:335–347.
97. Ayer A, Storer C, Tatham EL, Scott RH. The effects of changing intracellular Ca<sup>2+</sup> buffering on the excitability of cultured dorsal root ganglion neurons. *Neurosci Lett*. 1999;271:171–174.
98. Dib-Hajj SD, Fjell J, Cummins TR, Zheng Z, Fried K, LaMotte R, Black JA, Waxman SG. Plasticity of sodium channel expression in DRG neurons in the chronic constriction injury model of neuropathic pain. *Pain*. 1999;83:591–600.
99. Luo ZD, Chaplan SR, Higuera ES, Sorkin LS, Stauderman KA, Williams ME, Yaksh TL. Upregulation of dorsal root ganglion (alpha)2(delta) calcium channel subunit and its correlation with allodynia in spinal nerve-injured rats. *J Neurosci*. 2001;21:1868–1875.
100. Chung K, Chung JM. Sympathetic sprouting in the dorsal root ganglion after spinal nerve ligation: Evidence of regenerative collateral sprouting. *Brain Res*. 2001;895:204–212.
101. Lee BH, Yoon YW, Chung K, Chang JM. Comparison of sympathetic sprouting in sensory ganglia in three animal models of neuropathic pain. *Exp Brain Res*. 1998;120:432–438.
102. Ramer MS, Bisby MA. Rapid sprouting of sympathetic axons in dorsal root ganglia of rats with a chronic constriction injury. *Pain*. 1997;70:237–244.
103. Ramer MS, Thompson SW, McMahon SB. Causes

and consequences of sympathetic basket formation in dorsal root ganglia. *Pain*. 1999;Suppl 6:S111–120.

104. Ramer MS, French GD, Bisby MA. Wallerian degeneration is required for both neuropathic pain and sympathetic sprouting into the DRG. *Pain*. 1997;72:71–78.

105. Boden SD. Abnormal magnetic-resonance scans in asymptomatic subjects. *J Bone Joint Surg*. 1990;72A:403–408.

106. Jensen MC, Brant-zawadzski MN, Obvchowski N, Modic MT, Malkasian D, Ross JS. Magnetic resonance imaging of the lumbar spine in people without low back pain. *N Engl J Med*. 1994;331:60–73.

107. Weishaupt D, Zanetti M, Hodler J, Boos N. MR imaging of the lumbar spine: Prevalence of intervertebral disc extrusion and sequestration, nerve root compression, end plate abnormalities, and osteoarthritis of the facet joints in asymptomatic volunteers. *Radiol*. 1998;209: 661–666.

108. Milette PC. Radiculopathy, radicular pain, radiating pain, referred pain: What are we really talking about? *Radiol*. 1994;192:280–282.

109. Ohnmeiss DD, Vanharanta H, Ekholm J. Relation between pain location and disc pathology: A study of pain drawings and CT/discography. *Clin J Pain*. 1999;15:210–217.

110. Jonsson B, Stromqvist B. Motor affliction of the L5 nerve root in lumbar nerve root compression syndromes. *Spine*. 1995;20:2012–2015.

111. An HS. Cervical root entrapment. *Hand Clin*. 1996; 12:719–730.

112. Burkman KA, Gaines RW Jr, Kashani SR, Smith RD. Herpes zoster: a consideration in the differential diagnosis of radiculopathy. *Arch Phys Med Rehabil*. 1988;69:132–134.

113. Butler DS. Adverse mechanical tension in the nervous system: a model for assessment and treatment. *Aus J Physiother*. 1989;35:227–238.

114. Chow R, Adams R, Herbert R. Straight leg raise test high reliability is not a motor memory artefact. *Aus J Physiother*. 1994;40:107–111.

115. Hall T, Hepburn M, Elvey RL. The effect of lumbosacral posture on a modification of the straight leg raise test. *Physiother*. 1993;79:566–570.

116. Lee RY, Munn J. Passive moment about the hip in straight leg raising. *Clin Biomech*. 2000;15:330–334.

117. BenDebba M, Torgerson WS, Long DM. A validated, practical classification procedure for many persistent low back pain patients. *Pain*. 2000;87:89–97.

118. Ohnmeiss DD, Guyer RD, Hochschuler SH. Related Articles Laser disc decompression. The importance of proper patient selection. *Spine*. 1994;19:2054–2058.

119. Cameron DM, Bohannon RW, Owen SV. Influence of hip position on measurements of the straight leg raise test. *J Orthop Sports Phys Ther*. 1994;19:168–172.

120. Johnson EK, Chiarello CM. The slump test: the effects of head and lower extremity position on knee extension. *J Orthop Sports Phys Ther*. 1997;26:310–317.

121. Lew PC, Briggs CA. Relationship between the cervical

component of the slump test and change in hamstring muscle tension. *Man Ther*. 1997;2:98–105.

122. Tanaka M, Nakahara S, Inoue H. A pathologic study of discs in the elderly; Separation between the cartilaginous endplate and vertebral body. *Spine*. 1993;18:1456–1462.

123. Yildizhan A, Pasaoglu A, Okten T, Ekinci N, Aycan K, Aral O. Intradural disc herniations pathogenesis, clinical picture, diagnosis and treatment. *Acta Neurochir*. 1991;110:160–165.

124. Panjabi MM, Takata K, Goel VK. Kinematics of Lumbar Intervertebral Foramen. *Spine*. 1983;8:348–357.

125. Sizer PS, Phelps V, Brismee JM. Differential diagnosis of local cervical syndrome versus cervical brachial syndrome. *Pain Prac*. 2001;1:21–35.

126. Indahl A, Haldorsen EH, Holm S, Reikeras O, Ursin H. Five-year follow-up study of a controlled clinical trial using light mobilization and an informative approach to low back pain. *Spine*. 1998;23:2625–2630.

127. Snook SS. The reduction of chronic nonspecific low back pain through the control of early morning lumbar flexion: a randomized controlled trial. *Spine*. 1998;23:2601–2607.

128. Komori H, Shinomiya K, Nakai O, Yamura S, Takeda S, Kohtaru F. The natural history of herniated nucleus pulposus with radiculopathy. *Spine*. 1996;21:225–229.

129. Matthews JA. De waarde van epidurografie bij de beoordeling van de weding van manipulatie en tractie bij lumbale discusproblemen. *Tijdschr Ned Vereniging Orthop*. 1981; 1:23–43.

130. Onel D, Tuzkaci M, Sari H, Demir K. Computed tomographic investigation of the effect of traction on lumbar disc herniations. *Spine*. 1989;14:82–90.

131. Guechev G, Guechev A. Fast dynamics of voluntary muscle strength and motor evoked potentials after traction therapy in patient with lumbosacral root lesion. *Electromyogr Clin Neurophysiol*. 1996;36:195–197.

132. Meszaros TF, Olson R, Kulig K, Creighton D, Czarnecki E. Effect of 10%, 30%, and 60% body weight traction on the straight leg raise test of symptomatic patients with low back pain. *J Orthop Sports Phys Ther*. 2000;30:595–601.

133. Cyriax JH. *Illustrated Manual of Orthopaedic Medicine*. London, United Kingdom: Butterworths; 1989.

134. Donelson RG. Mechanical assessment of low back pain: part 4. *J Musc Med*. 1998;15:28–34, 39.

135. Sufka A, Hauger B, Trenary M, Bishop B, Hagen A, Lozon R, Martens B. Related Articles Centralization of low back pain and perceived functional outcome. *J Orthop Sports Phys Ther*. 1998;27:205–212.

136. Werneke M, Hart DL, Cook D. A descriptive study of the centralization phenomenon. A prospective analysis. *Spine*. 1999;24:676–683.

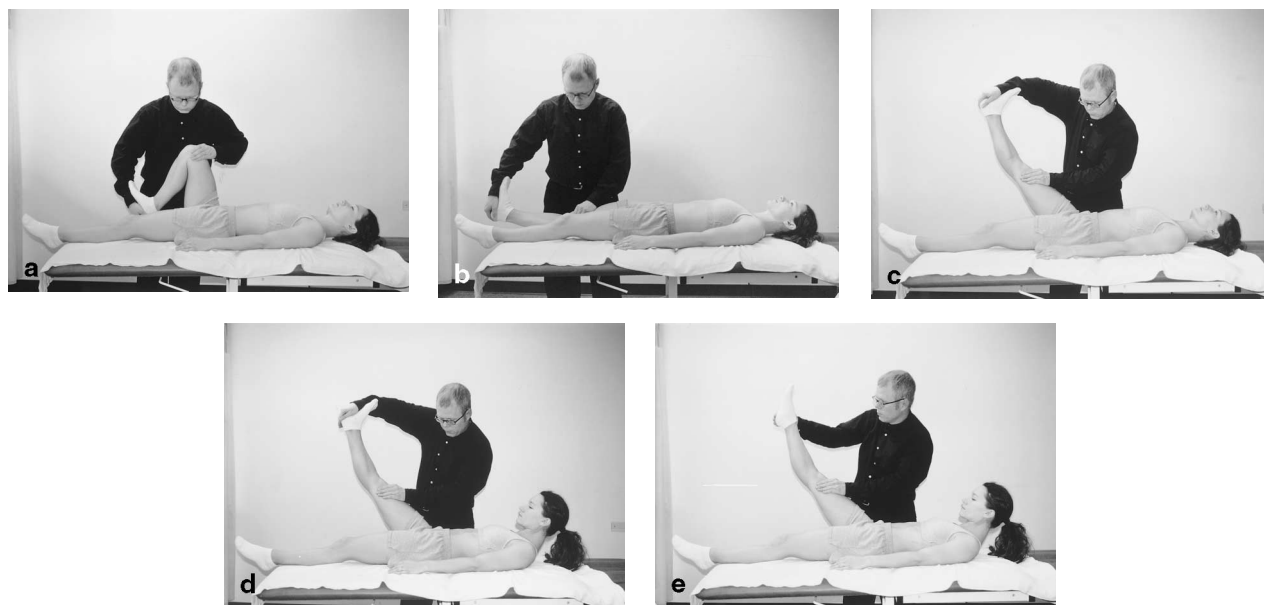137. Heavner JE, Racz GB, Raj PP. Percutaneous Epidural Neuroplasty: Prospective evaluation of 0.9% NaCl versus 10% NaCl with or without hyaluronidase. *Reg Anesth Pain Med*. 1999;24:202–207.

138. Anderson SR, Racz GB, Heavner. Evolution of epidural lysis of adhesions. *Pain Phys*. 2000;3:262–270.

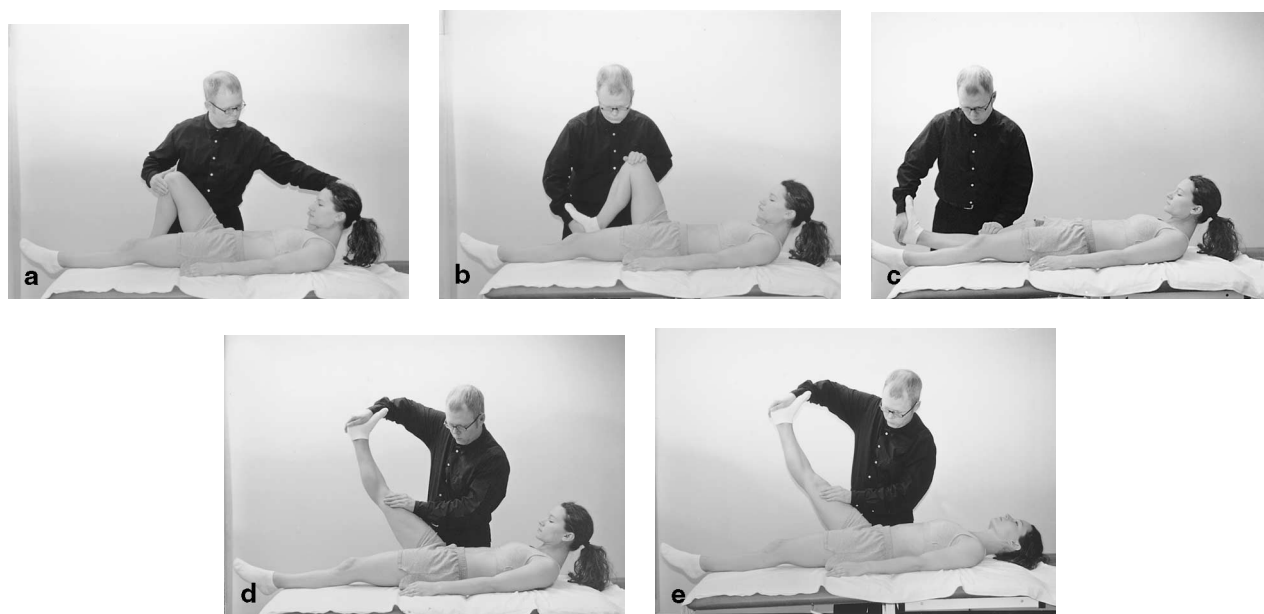139. Racz GB, Heavner JE, Raj PP. Percutaneous epidural neuroplasty: Prosepctive one-year follow-up. *Pain Dig*. 1999;9:97–102.

140. Racz GB, Noe C, Heavner JE. Selective spinal injections for lower back pain. *Curr Rev Pain*. 1999;3:333–341.

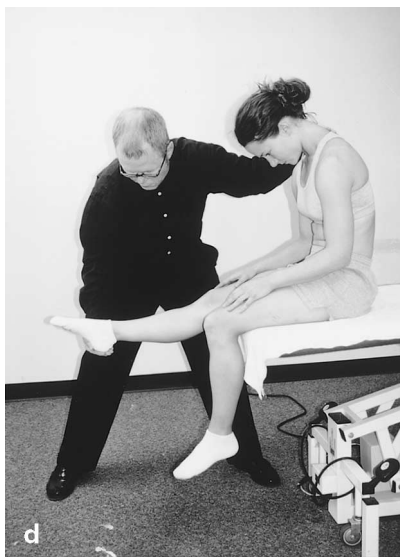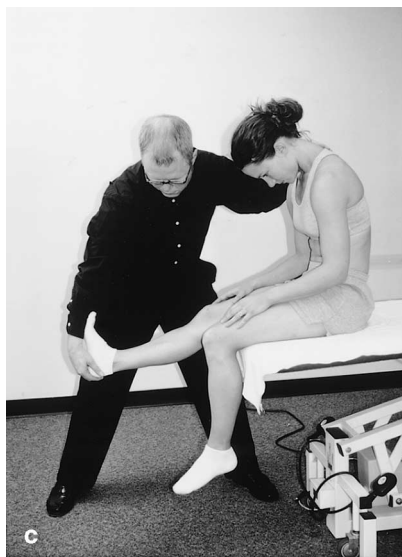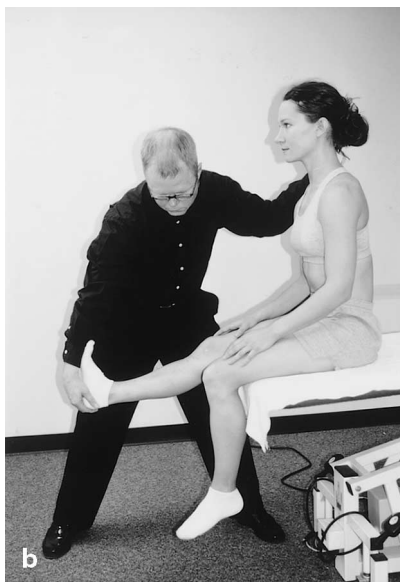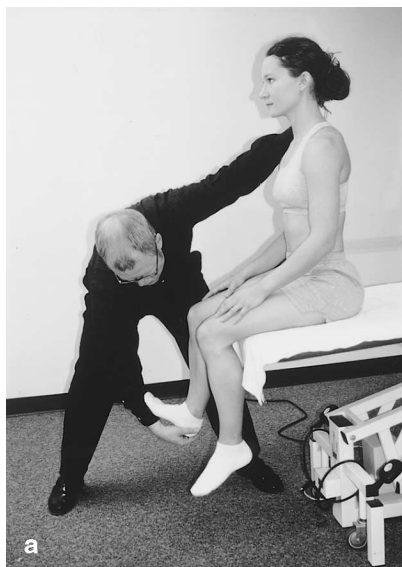141. Racz GB, Heavner JE, Raj PP. Percutaneous epidural neuroplasty. *Sem Anesth*. 1997;16:302–312.



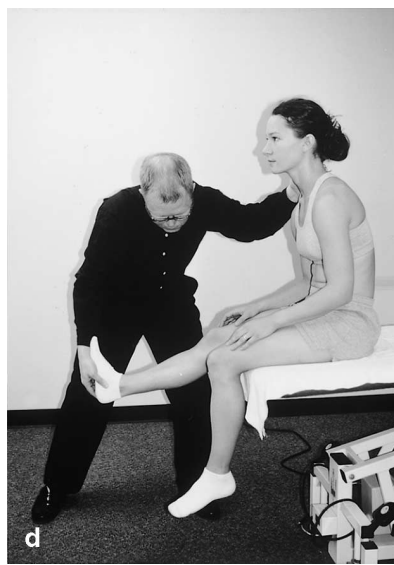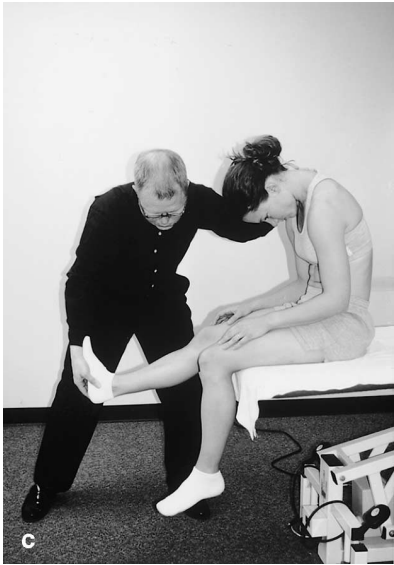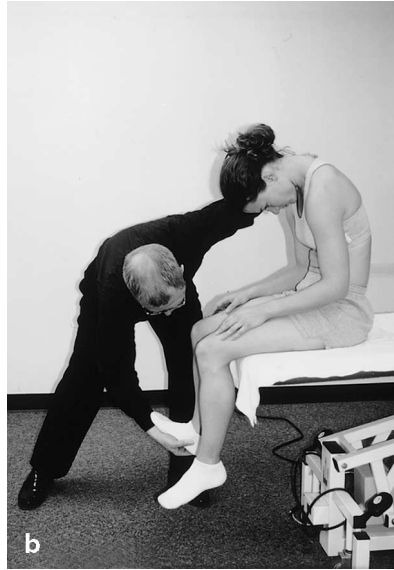
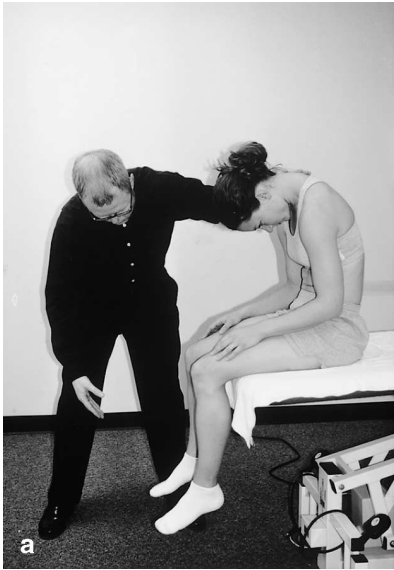**Appendix A.** Straight Leg Raise, Distal Initiation (SLRDI). (a) Dorsiflexion of ankle/foot, thus pre-tensioning nerve tissue distal to popliteal tension point; (b) Extend knee and hip to attain starting position for SLR; (c) SLR movement, maintaining ankle/foot dorsiflexion; (d) Chin tuck with neck flexion; (e) Ankle/foot plantar flexion.



**Appendix B.** Straight Leg Raise, Proximal Initiation (SLRPI). (a) Chin tuck with neck flexion; (b) Dorsiflexion of ankle/foot; (c) Extend knee and hip to attain starting position for SLR; (d) SLR movement, maintaining ankle/foot dorsiflexion; (e) Return of head back to the mat.



**Appendix C. Slump Distal Initiation (SDI).** (a) Dorsiflexion of ankle/foot, thus pre-tensioning nerve tissue distal to popliteal tension point; (b) Knee extension, maintaining ankle/foot dorsiflexion; (c) Chin tuck & neck flexion, followed by trunk slump; (d) Ankle/foot plantar flexion.



**Appendix D. Slump, Proximal Initiation (SPI).** (a) Chin tuck & neck flexion, followed by trunk slump; (b) Dorsiflexion of ankle/foot, thus pre-tensioning nerve tissue distal to popliteal tension point; (c) Knee extension, maintaining ankle/foot dorsiflexion; (d) Head raise + neck extension, while maintaining trunk slump.